

INTERTRANSVERSE PROCESS ARTHRODESIS: EFFICACY OF DC STIMULATION IN A NICOTINE EXPOSURE MODEL

*France, JC; +Norman, TL; *Buchanan, M; *Scheel, M; *Veale, M; *Ackerman, E; *Clovis, NB; *Kish, VL
 +*West Virginia University

INTRODUCTION

Nicotine has been shown to have an inhibitory effect on the vascular ingrowth of autogenous bone graft leading to prolonged or inhibited bone healing (2,5,6). The effect of nicotine has been suggested as a reason for decreased effectiveness in spinal fusion procedures in patients who smoke (5). In our previous work, direct current electrical stimulation was shown to enhance intertransverse process (ITP) fusion in a rabbit model (3). In this study, the effect of DC current stimulation was investigated in rabbits exposed to nicotine. It was hypothesized that direct current stimulation would ameliorate the debilitating effect of nicotine on bone healing.

METHODS

Thirty adult (1 year) 4.0 kg New Zealand white rabbits were obtained and randomly divided into three test groups (n = 10). Each group received a single level posterolateral, intertransverse process fusion with autologous iliac crest bone (1) (Figure 1). A control group received an autologous bone graft fusion. A nicotine group (Nic) received the autologous bone graft fusion and a 10.5 mg nicotine patch. A nicotine/stimulator group (Nic/Stim) received spine fusion with the addition of a 100-microamp direct current stimulator (EBI SpF-2T) (EBI Medical Systems, Inc., Parsippany, NJ) and the 10.5 mg nicotine patch. The fusion masses (L5-L6) and the adjacent unfused control segment (L4-L5) were harvested from each animal at five weeks. Radiographs of the segments were viewed and graded by orthopedic surgeons using a scale of three (fused) to one (lack of fusion). The fused segment was defined as complete fusion with no lucent clefts or radiolucencies. The unfused segment was defined as 100% clefts. A grade of two defined partial fusion, indicated by the presence of partial clefts. The lumbar spine segments were also manually palpated and evaluated for fusion based on motion and graded as fused or not fused.

RESULTS

The fusion rates of the Nic/Stim group determined by manual palpation was significantly ($p < 0.05$) higher than controls (Figure 2). The fusion rate of the Nic group was also significantly ($p < 0.05$) greater than the control group. The average fusion rates were: Nic/Stim ($85\% \pm 12.7\%$), Nic ($66.0\% \pm 7.2\%$) and Control ($37.5\% \pm 12.5\%$). Radiographic assessment revealed significantly ($p < 0.0151$) better trabeculation and bone incorporation in the Nic/Stim specimens (2.17 ± 0.38) compared to the control group (1.56 ± 0.46) (Figure 3). The Nic specimens also exhibited a higher mean (1.91 ± 0.33) than the Control group although the difference was not significant.

DISCUSSION

DC stimulation significantly improved healing in rabbits exposed to nicotine compared to those exposed to nicotine alone and compared to the control group as hypothesized. Surprisingly, the nicotine group showed improved healing compared to the control group. Nicotine has been shown to have an inhibitory effect on the vascular ingrowth of autogenous bone graft leading to prolonged or inhibited bone healing and this effect has been suggested as the reason for decreased effectiveness in spinal fusion procedures in patients who smoke. However, results of this study indicated improved fusion rates with nicotine delivered via patch. Because tobacco smoke is a complex mixture of over 4,000 chemicals, it is difficult to predict the effect of nicotine delivered via the use of tobacco. Results of the current study are supported by a recent study that demonstrated that nicotine stimulates angiogenesis (4).

The results of this study indicate that DC stimulation significantly enhanced healing of intertransverse process fusion in rabbits exposed to nicotine. In addition, we found that the nicotine delivered via the patch enhanced healing compared to control specimens.

REFERENCES

1. Boden SD et al., Spine 20:412-420, 1995.
2. Daftari TK et al., Spine 19:904-911, 1994.
3. France JC et al., Spine 26:1002-1008, 2001.
4. Heeschen C et al., Nat Med 7:833-838, 2001.
5. Hollinger JO et al., J Biomed Mater Res 45:294-301, 1999.
6. Riebel G et al., Spine 20:2198-2202, 1995.

ACKNOWLEDGEMENT

Funding for this research was provided by North American Spine Society (NASS). Suzanne Smith provided technical support.

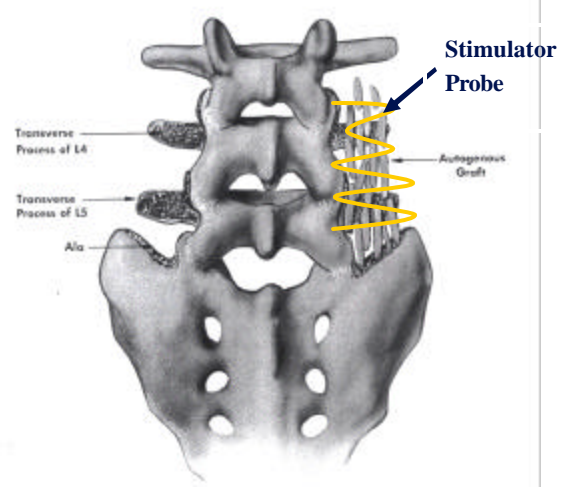


Figure 1. Diagram of intertransverse fusion and a stimulator probe.

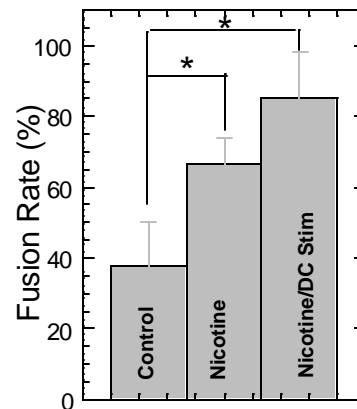


Figure 2. Fusion rate determined by manual palpation.

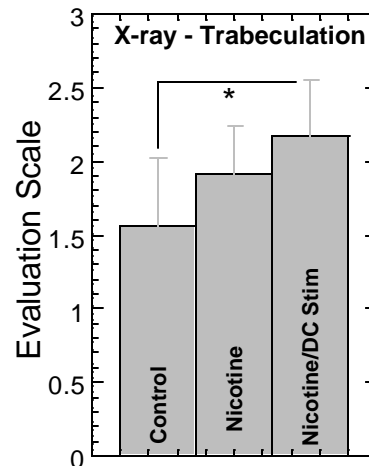


Figure 3. Trabeculation score determined from radiograph. Higher score reflects more trabeculation.