

A Multi-Modal Pipeline for Building Large-Scale Normative and Pathological Databases to Assist with Personalized Care of Hip Disorders

Nazgol Tavabi, Mohammadreza Movahhedi, Mallika Singh, Jin-Young Kim, Shilpa Suresh, Young-Jo Kim, Eduardo Novais, Ata M. Kiapour
Department of Orthopedic Surgery, Boston Children's Hospital and Harvard Medical School, Boston, MA

Nazgol.Tavabi@childrens.harvard.edu

Disclosures: N. Tavabi: None. M. Movahhedi: None. M. Singh: None. J. Kim: None. S. Suresh: None. Y. Kim: 3C; Orthopediatrics. 4; Cytex, Imagen. 8; Journal of Hip Preservation Surgery, Orthopedics Review, Osteoarthritis and Cartilage. E. Novais: None. A. Kiapour: 3B; MIACH Orthopaedics. 8; BMC musculoskeletal disorders and American Journal of Sports Medicine.

INTRODUCTION: Hip is one of the most common injured joints, particularly among adolescents and young adults. Subtle or significant changes in hip morphology have shown to alter its biomechanics, and have been suggested as the primary risk factors, diagnostic markers, and treatment targets for most hip injuries. Detailed evaluation of these anatomical features has a direct impact on the clinical care of patients with hip disorders. While some of these anatomical features can be readily measured from plane films (i.e., X-Ray), the more complex and clinically significant dysmorphologies require 3D evaluations (e.g., from CT or MRI). Comprehensive 3D evaluation of hip morphology is cumbersome and often neglected clinically. There are growing interests and efforts to incorporate automatic 3D image segmentations and assessments into the clinical workflow to facilitate 3D morphology assessments. There is a lack of population-specific (e.g., age and sex-based) thresholds for those assessments as the existing data is based on 2D measurements from X-Ray images and are not directly translatable to 3D assessments. The objective of this study was to leverage one of the largest databases of pediatric and young-adults pelvis/hip CT scans to generate a comprehensive registry of normal and pathologic hip morphology to assist with patient specific diagnosis and treatment planning.

METHODS: A multi-modal pipeline was developed (Figure 1) to generate a comprehensive registry of normal and pathologic hip morphology. The pipeline included natural language processing module to process the clinical and radiology notes to identify hip status (i.e., normal vs pathologic). Example of patients with normal hip CT scans include those with gastrointestinal problems. The selected hip CT scans were quality checked--using a classifier to identify low quality images-- and segmented into 3D models using a deep learning module. A comprehensive rule-based pipeline was then used to measure 40+ hip anatomical features in 3D including femoral measurements, acetabular measurements and hip coverage. This pipeline was used to analyze the available CT scans of patients with both hip related complaints (e.g., hip pain) and other complaints (e.g., appendicitis) from 2012-2000.

RESULTS: Our NLP pipeline identified 18,154 normal and 7,008 pathologic hip CT-Scans (accuracy: 0.98). Out of which, 17,613 were deemed "good quality" and used to generate 3D hip models (Dice: 0.98+/-0.03; Surface Error<1mm), which was then used to assess hip morphology (Error<2mm & 4 degrees). The analysis resulted in a comprehensive database of normal hip development from birth to early adulthood (24,000+ normal hips). Using this normative data, we have established normal hip development charts for both males and females (Figure 2).

DISCUSSION: Leveraging existing multi-modal medical data, we developed a fully automated pipeline that extracts anatomical features from the hip joint in 3D, specify the measurements that fall outside of the normal range compared to its population (same age, same sex), and precisely reveal the abnormalities. This rich database is currently being used to develop normative growth charts for detailed anatomical features of the hip throughout the skeletal growth and maturation. These include detailed 3D assessment of proximal femur, femoral head-neck junction, acetabulum, hip coverage and sacropelvic alignment. We are planning to publicly release this data to assist with personalized assessment of hip dysmorphology.

SIGNIFICANCE: The current project highlights the feasibility of multi-modal approaches to process existing clinical data to generate large-scale registries, which can then be used to improve care through evidence-based personalized diagnosis and treatment planning.

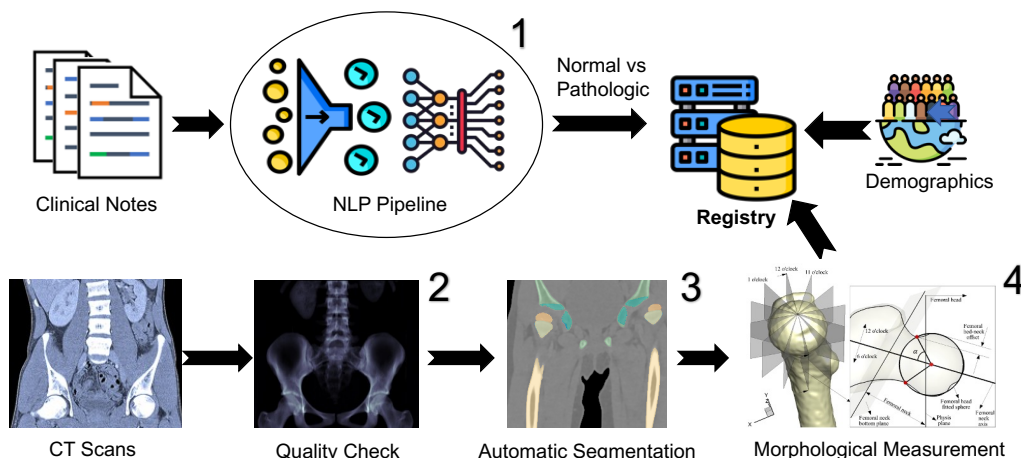


Figure 1: Multi-modal pipeline (clinical text and medical images) for building registry for personalized hip care.

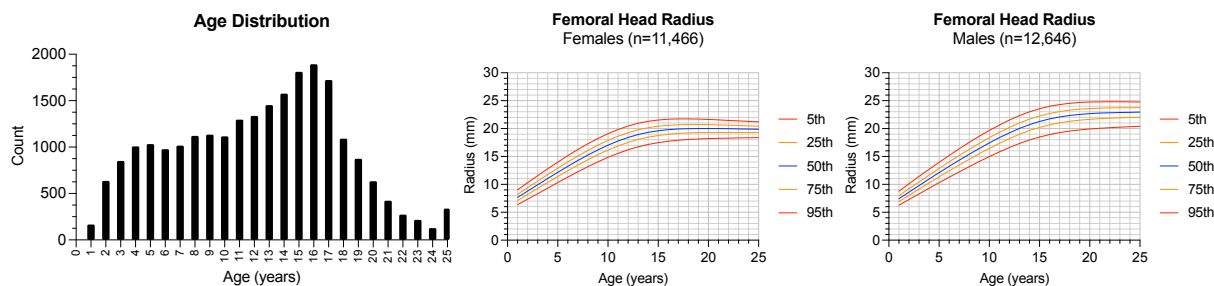


Figure 2: Distribution of the normative hips and sample hip growth percentile charts.