

The Role of Paraspinal Muscles in Outcomes after Decompression and Fusion Surgery in Patients with Degenerative Spondylolisthesis

Ali. E. Guven^{1,2}, MD; Lukas Schönnagel^{1,2}, MD; Jiaqi Zhu⁴, Thomas Caffard^{1,3}, MD; Soji Tani¹, PhD, MD; Roland Duculan¹, MD; Gaston Camino-Willhuber¹, MD; Maximilian Muellner^{1,2}, MD; Henryk Haffer^{1,2}, MD; Jennifer Shue¹, MS; Andrew A. Sama¹, MD; Frank P. Cammisa¹, MD; Federico P. Girardi¹, MD; Carol A. Mancuso¹, MD; Alexander P. Hughes¹, MD

¹ Hospital for Special Surgery, New York City, NY, USA. ² Center for Musculoskeletal Surgery, Charité - Universitätsmedizin Berlin. ³ Department of Orthopedic Surgery, University of Ulm, Ulm, Germany. ⁴ Department of Epidemiology and Biostatistics, Hospital for Special Surgery, Weill Cornell Medicine, New York City, NY, USA.

Disclosures: The authors have nothing to disclose.

Introduction: Decompression and fusion surgery is a widely accepted treatment for symptomatic degenerative lumbar spinal stenosis (DLS), which substantially improves functional outcomes in symptomatic patients who are unresponsive to conservative treatment. However, the degree of improvement varies among patients following surgery. Fatty infiltration (FI) of the paraspinal muscles (PM), specifically the erector spinae, multifidus, and psoas has been linked to a number of spinal conditions, such as lower back pain and sagittal misalignment likely due to its role in maintaining spinal stability. However, the effect of PM on outcomes after lumbar fusion surgery has not been widely investigated. This study aimed to examine the influence of FI on the improvement in the Oswestry Disability Index (ODI) in patients undergoing decompression and fusion surgery for symptomatic DLS.

Methods: We retrospectively analyzed prospectively enrolled patients with symptomatic DLS undergoing decompression and fusion surgery. Patients with only decompression surgery, missing follow-up, absent imaging, or inadequate image quality were excluded. The ODI of patients was assessed pre-operatively and two years postoperatively. A representative cross-sectional area of the PM was measured on a T2-weighted axial MRI sequence at the upper endplate of L4. The FI of the erector spinae, multifidus, and psoas was determined using custom software (MuscleEval). Improvement in the ODI was calculated as the difference between the pre-operative and follow-up ODI, with higher values indicating greater improvement. Based on the literature, a 10-point improvement cut-off was defined as the minimum clinically important difference (MCID). The impact of FI on ODI improvement was analyzed using logistic regression to calculate the odds ratio for an improvement in ODI \geq MCID, adjusting for age, sex, and BMI. Patients with a baseline ODI below ten were excluded from this analysis, as they could not improve by 10 points.

Results: 138 patients were included in the final analysis, with only two lost to follow-up. The median age was 68 years (IQR 62 – 73), the median BMI was 29 kg/m² (IQR 26 - 33), 70.3% were female, 73.9% of patients had spondylolisthesis Grade 1, and the most common level of DLS was L4/5 (63.8%). The median preoperative ODI was 23 (IQR 17 - 28) with a median improvement of 13 (IQR 6 - 22), and 64.8% of patients had an MCID change in ODI. The median FI of the erector spinae was 40.0% (IQR 33.3% - 47.0%), of the multifidus 59.9% (IQR 50.4% - 70.1%), and for the psoas 6.0% (IQR 3.3% - 9.3%). Patients with a multifidus FI $< 60\%$ had a median ODI improvement of 17 points, while patients with a multifidus FI $\geq 60\%$ had a median gain of 13 points ($p = 0.047$). Figure 1 represents the univariable logistic regression for the multifidus muscle. With increased FI infiltration, the likelihood of clinically significant improvement (>10 points) decreases significantly ($p = 0.004$). In the multivariable linear regression, the FI of the erector spinae and multifidus had a significant effect on the OR for the likelihood of MCID improvement in ODI (erector spinae: OR: 0.94, 95% CI: 0.90 - 0.99, $p = 0.010$; multifidus: OR: 0.93, 95% CI: 0.90 - 0.97, $p < 0.001$), while the psoas had no significant effect ($p = 0.469$).

Discussion: This study demonstrates that FI of the PM, specifically the erector spinae and multifidus, is significantly associated with improved ODI following decompression and fusion surgery for symptomatic DLS. Patients with lower FI in the erector spinae and multifidus were more likely to experience a clinically significant improvement in ODI. However, FI in the psoas muscle did not significantly impact the outcome. These findings highlight the importance of considering the FI of PM, particularly the erector spinae and multifidus, in assessing and managing patients undergoing decompression and fusion surgery for symptomatic DLS. Further research is needed to investigate potential interventions to reduce FI and optimize patient outcomes in this population.

SIGNIFICANCE/CLINICAL RELEVANCE: This study demonstrates the clinical relevance of the paraspinal musculature, emphasizing the need to consider muscle health in surgical planning and post-operative management.

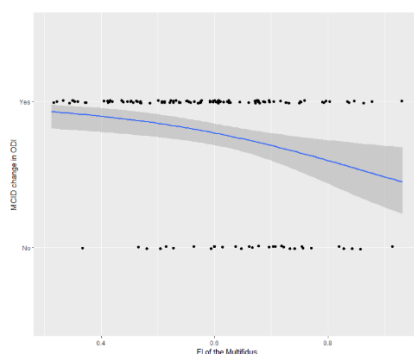


Figure 1: Visual representation of the univariable logistic regression. With increased FI of the multifidus, the likelihood, represented by the blue line, of minimal clinically significant improvement (≥ 10 points) in ODI two years after surgery decreases ($p = 0.004$).

FI = Fatty infiltration, MCID = Minimal clinically important difference

