

Androgen Treatment Exhibits A Protective Role Against Focal Erosions in TNF-Induced Inflammatory Arthritis in Mice

Kiana L. Chen^{1,2}, Adelaide Weidner³, Olga I. Astapova^{4,5}, Edward M. Schwarz^{1,2,6}, and Homaira Rahimi^{2,7}

¹Department of Pathology, ²Center for Musculoskeletal Research, ³Department of Environmental Medicine, ⁴Department of Medicine, ⁵Division of Endocrinology and Metabolism, ⁶Department of Orthopedics, ⁷Department of Pediatrics, University of Rochester School of Medicine and Dentistry, Rochester, NY, USA

Disclosures: The authors have no disclosures

INTRODUCTION: Rheumatoid arthritis (RA) is characterized by chronic joint inflammation and bone erosion and is female predominant. The TNF-transgenic (TNF-Tg) murine model of RA develops inflammatory erosive arthritis and displays a sex difference in disease, with females having earlier onset and more severe disease than males (1). Studies suggest androgens provide a protective effect against joint disease and TNF-mediated bone erosion (2). We have previously shown that the removal of endogenous sex hormones in TNF-Tg males significantly worsens their inflammatory erosive disease. Here, we investigated whether treatment of TNF-Tg mice with exogenous androgen ameliorates erosive disease.

METHODS: All animal studies were approved by the University of Rochester Committee for Animal Resources within an AAALAC accredited vivarium. TNF-Tg male mice were orchietomized followed by subcutaneous implantation of either 5 α -dihydrotestosterone (DHT) or placebo pellet at 1-month old (n = 3/group). Pellets released 1.5mg of DHT or placebo for 60 days (0.025mg/day). Micro-computed tomography (μ CT) scans of hindpaws were taken at 3-months old and compared with μ CT data of same age intact TNF-Tg males and orchietomized wildtype (WT) males (n = 4-6 paws/group). The total bone volumes (mm³) of the cuboid, talus, and navicular and lateral intermediate cuneiform were compared between all groups. The volumes of the periarticular metatarsals were compared between TNF-Tg groups. Paw deformation scores and weights were taken weekly from 1 to 3 months old. Same age sham TNF-Tg male mice weekly weights were compared between orchietomized TNF-Tg groups. Serum and paws were obtained for analysis and histology. Values are reported as the mean \pm standard deviation.

RESULTS: Placebo-treated orchietomized TNF-Tg mice had significantly more bone volume loss than DHT-treated orchietomized TNF-Tg mice and other cohorts in the cuboid (0.34 \pm 0.03 Orchietomized TNF-Tg + Placebo; 0.43 \pm 0.02 Orchietomized TNF-Tg + DHT; 0.43 \pm 0.06 Intact TNF-Tg; 0.45 \pm 0.05 Orchietomized WT), talus (0.97 \pm 0.09 Orchietomized TNF-Tg + Placebo; 1.10 \pm 0.06 Orchietomized TNF-Tg + DHT; 1.21 \pm 0.07 Intact TNF-Tg; 1.12 \pm 0.05 Orchietomized WT), and navicular and lateral intermediate cuneiform (0.78 \pm 0.04 Orchietomized TNF-Tg + Placebo; 0.87 \pm 0.03 Orchietomized TNF-Tg + DHT; 0.94 \pm 0.04 Intact TNF-Tg; 0.93 \pm 0.04 Orchietomized WT) (Fig 1B-D). Segmented hindpaw images of the TNF-Tg cohorts showed bone erosion in the periarticular regions of the metatarsals (Fig 1E-G). Placebo treated orchietomized mice had less bone volume in the distal metatarsals than DHT-treated orchietomized TNF-Tg mice and intact TNF-Tg mice (0.23 \pm 0.05 Orchietomized TNF-Tg + Placebo; 0.28 \pm 0.07 Orchietomized TNF-Tg + DHT; 0.27 \pm 0.07 Intact TNF-Tg) (Fig 1H). Orchietomized TNF-Tg mice with placebo had significantly higher mean deformation scores at 4 weeks post-surgery (p = 0.03) (Fig 2A). Orchietomized TNF-Tg mice also gained significantly less weight than sham TNF-Tg mice by 6 weeks post-surgery (p = 0.03). DHT treatment of orchietomized TNF-Tg mice resolves that weight loss over time (Fig 2B).

DISCUSSION: Androgen treated orchietomized arthritic mice had significantly improved bone volumes, limiting bone erosion even in the presence of ongoing inflammation. Clinical measures of weight loss and arthritis also improve with androgen treatment. These finding suggests sex hormones have a relationship with the immune system in inflammatory-erosive disease that warrants further study. Histological analysis of the paws and osteoclastogenic cultures of bone marrow are ongoing to delineate the mechanism of androgen effects on inflammation.

SIGNIFICANCE/CLINICAL RELEVANCE: This research investigates the influence of androgen on inflammatory bone erosion. This will provide further introspection and potential explanations into the sexual differences seen in rheumatoid arthritis and other autoimmune diseases.

REFERENCES: 1) Bell R.D. et al. *Arthritis Rheumatol* 71(9): 1512-1523. 2019. 2) Traish A et al. *J Clin Med* 7(12): 549. 2018.

ACKNOWLEDGEMENTS: NIH/NIAMS P30 AR061307, K08 AR067885, T32 AR053459, R01 AR56702, NIH/NICHD HD068373-04

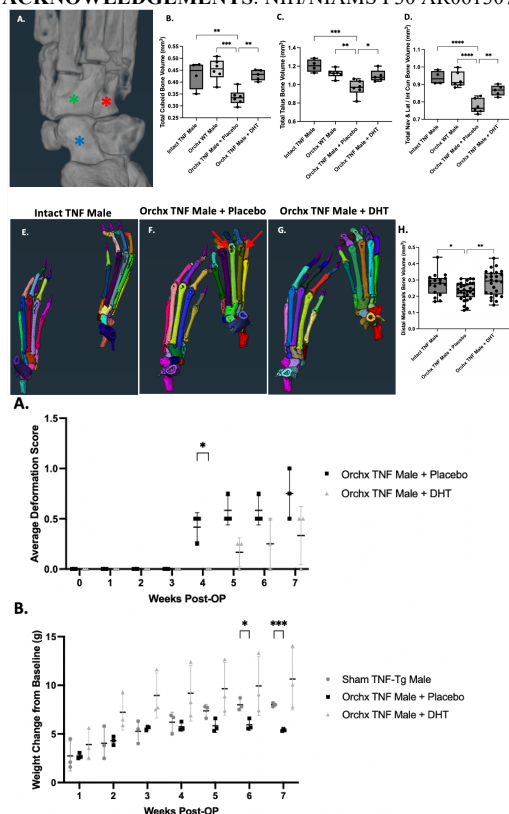


Figure 1. DHT Decreases Bone Erosions in Orchietomized TNF-Tg Mice. μ CT imaged hindpaw bones were segmented to determine total bone volume (mm³) of the cuboid (A, red asterisk), talus (A, blue asterisk), and navicular and lateral intermediate cuneiform (A, green asterisk) for all groups (n = 4-6 paws/group). Orchietomized TNF-Tg mice treated with placebo have significantly greater bone loss in the cuboid (B), talus (C), navicular and lateral intermediate cuneiform (D) compared to the other cohorts. Placebo treated orchietomized TNF-Tg mice also had significantly less bone volume in the distal ends of the metatarsals that showed periarticular erosions reminiscent of erosions seen in RA patients (F, arrows; H). Orchietomized mice treated with DHT had significantly greater bone volumes than orchietomized mice treated with placebo, exhibiting that DHT treatment decreases bone erosion. Mid-hindpaw bone volume analysis was performed using a one-way ANOVA with Tukey's multiple comparisons. Metatarsal bone volume analysis was performed using a one-way ANOVA with Fisher's LSD test. * = p<0.05; ** = p<0.01; *** = p<0.001; **** = p<0.0001.

Figure 2. DHT-Treated Orchietomized TNF-Tg Mice have Improved Clinical Measures of Disease. Orchietomized mice treated with placebo and orchietomized mice treated with DHT had weekly deformation scoring of their paws after surgery (n = 3 mice/cohort) (A). There was a significant difference in the average deformation score at week 4 post-op, signifying that orchietomized mice treated with placebo displayed paw inflammation earlier than mice treated with DHT. Orchietomized TNF-Tg mice treated with placebo, orchietomized TNF-Tg mice treated with DHT, and sham TNF-Tg mice were also weighed weekly after surgery. The weight change from the baseline week (week 0) was compared between cohorts (B). Orchietomized mice has significantly less weight gain than sham TNF-Tg mice by week 6 post-op. DHT treatment of orchietomized mice ameliorates this weight loss over time. Average deformation score analysis was performed with multiple unpaired t-tests. Weight analysis was performed with a two-way ANOVA with Tukey's multiple comparisons. * = p<0.05, *** = p<0.001.