

## Entry Point-Transition Point Angle as a Novel 3-Dimensional Metric of Patellar Instability

Johannes Sieberer<sup>1</sup>, Nancy Park<sup>1</sup>, Albert Rancu<sup>1</sup>, Armita Manafzadeh<sup>1</sup>, Curtis McDonald<sup>1</sup>, Kristin Yu<sup>2</sup>, Daniel Wiznia<sup>1</sup>, John Fulkerson<sup>1</sup>

<sup>1</sup>Yale University, New Haven, CT, <sup>2</sup>Mayo Clinic, Rochester, MN

[Nancy.park@yale.edu](mailto:Nancy.park@yale.edu)

Disclosures: Johannes Sieberer (N) Nancy Park (N), Albert Rancu (N), Armita Manafzadeh (N), Curtis McDonald (N) Kristin Yu (N), Daniel Wiznia (Globus Medical, Materialise NV) John Fulkerson (N)

**INTRODUCTION:** 3-dimensional (3D) modeling has increasing utility in identifying differences in trochlear morphology in patients with patellar instability when compared to historical attempts in 2 dimensions (2D). Distortions in the proximal medial ridges of trochleas are a distinguishing feature of trochlear dysplasia. Recently, the entry-point to transition-point (EP-TP) angle was established as a novel 3D metric to quantify degree of dysplasia, as it captures the tracking of the patella within the trochlea. However, previous attempts relied on 3D prints, which are not widely accessible. The purpose of this study is to validate this new measurement and compare differences between patients with patellar instability and the general population.

**METHODS:** 23 patients with recurrent patellar dislocations who were treated by a single surgeon between January 2020 and July 2023 were included. The study received an institutional review board exemption. Individuals from the New Mexico Decedent Image Database with no history of patellar instability or patellofemoral pain were used to obtain CT images from the general population. 3D stereolithography (STL) models of distal femurs were generated from CT images using ScanIP. Minimum and maximum principal curvature maps were taken as screenshots from maps generated in MeshLab. 2 people independently conducted measurements using a custom measuring tool displaying anteroposterior views and curvature maps of the distal femur. The measurers were asked to locate the medial and lateral ridges, transition point, and apex of the trochlea groove for each femur. A Mann-Whitney U test was performed to evaluate whether the recurrent dislocators had higher EP-TP values. P-values below 0.01 were regarded as significant. Inter-class correlation (ICC) and the 95% confidence interval thereof, was computed for the two independent measurements.

**RESULTS:** A total of 46 femurs were measured, including 23 recurrent dislocators and 23 population femurs. The recurrent dislocator cohort had a mean EP-TP of 57.4 deg with a standard deviation of 16.9 deg. The general population cohort had a mean EP-TP of 13.3 deg with a standard deviation of 10.8 deg. EP-TP for dislocators and general population was significantly different. ( $p < 0.001$ ). ICC between raters was 0.805 with a 95%-confidence interval of 0.675 to 0.887.

**DISCUSSION:** EP-TP angle is a novel metric of trochlear dysplasia that highlights the lateral tracking of the patella as it enters the proximal trochlea. Patients with recurrent patellar instability have significantly higher EP-TP angles than the general population. Our ICC of 0.805 is considered “excellent,” but the high range of the confidence interval suggests that further studies with increased sample size are needed to establish a sufficiently accurate estimate for ICC. Additionally, future studies are needed to correlate EP-TP angles with clinical histories and better understand the utility in surgical practice.

**SIGNIFICANCE/CLINICAL RELEVANCE:** EP-TP angle is a novel metric that helps quantify trochlear dysplasia, which can help clinicians better understand patellar instability. In this study, we validate EP-TP angle by showing that EP-TP angle was significantly different between femurs of recurrent dislocators and the general population.

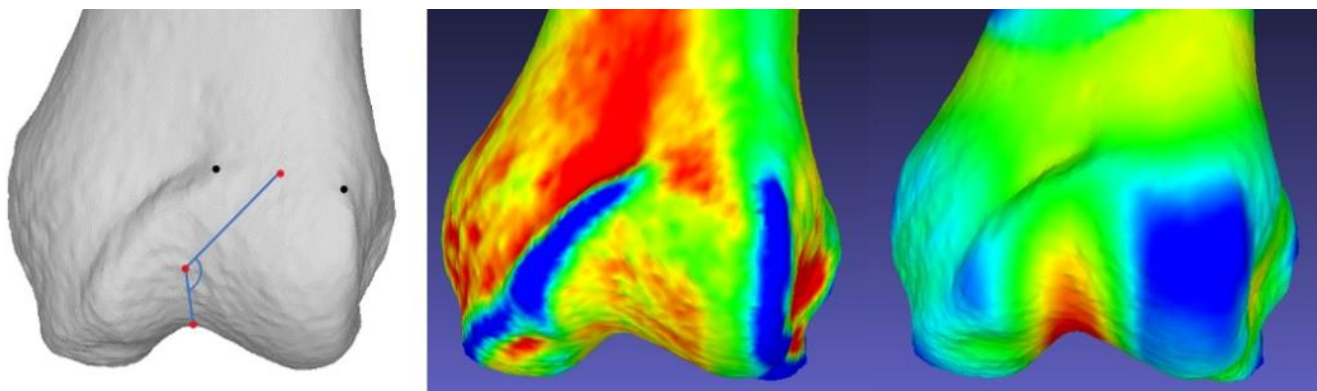


Figure 1: EPTP is defined as the 180 degrees minus the angle between a line from the apex of the trochlea groove to the transition point (TP) and a line from the TP to the entry point (EP). Thus, the acronym EP-TP. EP-TP is measured on an AP-view of the distal femur (left, with left medial and right lateral). The EP is the midpoint of the entry zone flanked by the medial and lateral ridges. Highlighted as blue in the curvature map in the middle. For patellar instability patients this entry zone is predominantly lateral. The patella moves medial and distal upon knee flexion until it reached the TP, where it continues to move straight down distally. The TP is accompanied with a deepening of the trochlea groove, highlighted in the curvature map to the right in red. The image to the left shows how the points were picked, and which angle was measured.