

# Longitudinal Statistical Shape Model Analysis of Post-Traumatic Osteoarthritis Development After Tibial Plafond Fractures

Andrew C. Peterson<sup>1</sup>, Jacob C. Benna<sup>1,2</sup>, Donald D. Anderson<sup>3</sup>, Maryam Soltanolkotabi<sup>1</sup>, Justin Haller<sup>1</sup>, Amy L. Lenz<sup>1</sup>  
<sup>1</sup>University of Utah, Salt Lake City, UT; <sup>2</sup>University of Nevada, Reno, NV; <sup>3</sup>University of Iowa, Iowa City, IA  
 andrew.c.peterson@utah.edu

**Disclosures:** Justin Haller (Stryker, Globus, Orthogrid, and Osteocentric)

**INTRODUCTION:** Post-traumatic osteoarthritis (PTOA) often develops after severe ankle injuries such as fractures of the tibial plafond, where the incidence has been reported to be as high as 40% [1]. This is particularly troublesome because these fractures disproportionately occur in young active individuals. Knowing how PTOA progresses in this context is crucial for optimizing treatment to enhance long-term joint health. However, the underlying mechanisms responsible for rapid PTOA development in these fractures remain unknown. This study aimed to objectively quantify the longitudinal development of PTOA in patients with tibial plafond fractures by analyzing loaded joint alignment and joint measurements (i.e., joint space width (JSW) [2]) from weightbearing computed tomography (WBCT) scans combined with statistical shape modeling (SSM). We hypothesized that two mechanisms exist that can be described by variations in joint alignment and joint space measurements for patients who either: 1) present rapidly with PTOA over the first 18 months post-operatively or 2) present with little to no joint degeneration.

**METHODS:** This investigation included 12 patients (age:  $49.7 \pm 12.1$  years; 3 females) treated for tibial plafond fractures at a Level-1 trauma center studied with IRB approval. WBCT scans were acquired for each patient at 6-, 12-, and 18-month post-operative visits. The tibia, fibula, talus, and calcaneus were automatically segmented in each WBCT scan using BoneLogic software (v2.1.1; Disior), with segmentation accuracy then manually verified in Mimics software (v24.0; Materialise). A multi-bone SSM (ShapeWorks; v6.3.2) analysis was performed on all 36 scans, categorizing them based on time points and OA severity. Severity groups were distinguished by a Richter OA grade of 0 or 1 (none/mild) or a grade of 3 or 4 (severe) in the tibiotalar joint at 18-months post-operative as rated by a musculoskeletal radiologist [3]. The none/mild and severe mean shapes at 6-, 12-, and 18-month time points were utilized for the loaded joint alignment and joint analyses. MATLAB (R2023a, MathWorks) was used to compare bone surfaces and compute joint distances. A repeated measures ANOVA was performed on the joint distance measurements to identify where any significant differences occurred within the joint between the severity groups at each time point.

**RESULTS:** The alignment analysis revealed greater variation in the none/mild group compared to the severe group. Specifically, between 6- and 12-months post-operative the posterior region of the calcaneus rotated inferiorly, and the talus shifted posteriorly in the none/mild group (Figure 1). Additionally, between 6- and 18-months postoperative the calcaneus also rotated/shifted medially. Minimal alignment variation was observed between any time points in the severe group. The joint distance analysis indicated primary differences in the subtalar joint and minimal differences in the tibiotalar, tibiofibular, and talofibular joints at any time point (Figure 2). Specifically, the none/mild group exhibited a significantly narrower joint space in the subtalar joint compared to the wider joint space in the severe group. The number of statistically different correspondence particles in the subtalar joint decreased from 6-months to 18-months.

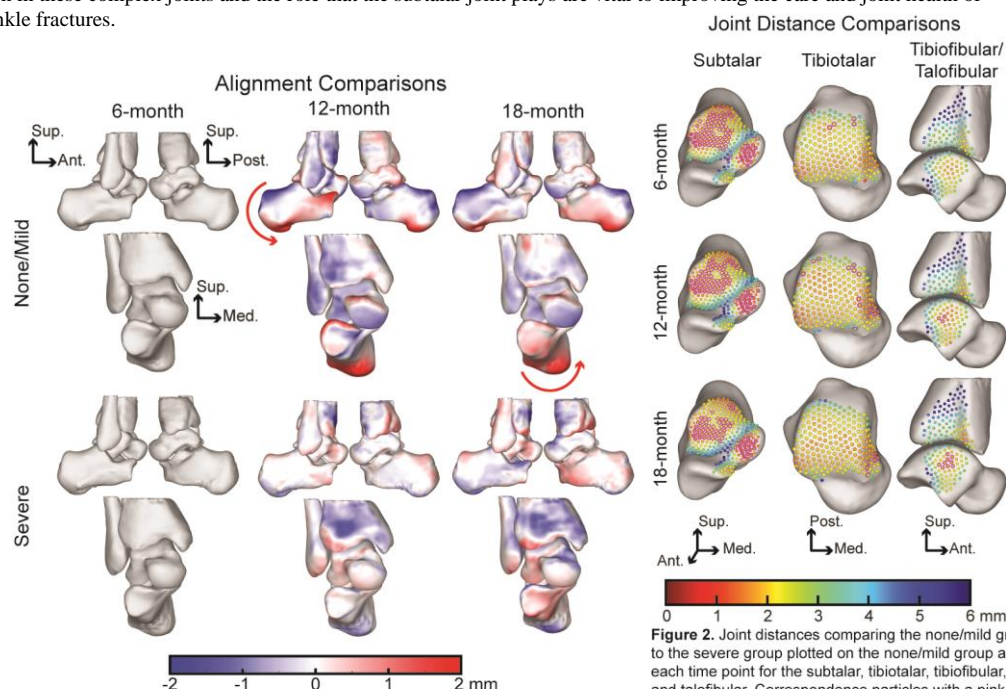
**DISCUSSION:** This analysis suggests that the subtalar joint plays a significant compensatory role when evaluating the alignment and joint distance differences between those patients who develop severe tibiotalar OA and those who do not. The rotation and shifting in the calcaneus and talus within the first 12-month post-operative period in conjunction with the significantly narrower subtalar joint distance highlights that the subtalar joint seems to be able to compensate post-operatively. We believe that individuals whose subtalar joint has the ability to compensate after acute ankle fractures do not develop OA as rapidly as those whose subtalar joint does not compensate, although the underlying mechanism enabling subtalar compensation is unknown but could include soft tissue hypermobility, a slight flatfoot presentation, or altered subtalar morphology. Future work will focus on identifying how and why the subtalar joint is compensating by including a larger sample size and a dynamic kinematic longitudinal analysis of a similar population. Understanding the dynamic nature of PTOA progression in these complex joints and the role that the subtalar joint plays are vital to improving the care and joint health of individuals recovering from acute ankle fractures.

## SIGNIFICANCE/CLINICAL

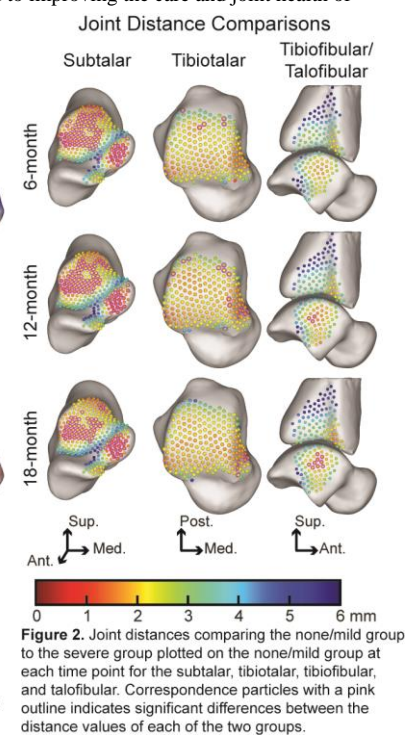
**RELEVANCE:** Our statistical shape modeling and joint analysis findings highlight the importance of investigating subtalar joint compensation adjacent to a pilon fracture surgical repair. These preliminary findings may indicate certain patients exhibit rapid onset of PTOA due to the inability of the subtalar joint to compensate.

**REFERENCES:** [1] Harris, A. et al. *Foot and Ankle Int.* 2006; 27(4), 256-265. [2] Day, M. et al. *Foot Ankle Int.* 2020; 41(9), 1106-1116 [3] Richter, M. et al. *Foot Ankle Clin.* 2022; 27(1), 13-36

**ACKNOWLEDGEMENTS:**  
 Funding provided by the Arthritis Foundation and NIH K01AR080221



**Figure 1.** Alignment visualization comparing 12-month and 18-month post-op for the none/mild and severe groups



**Figure 2.** Joint distances comparing the none/mild group to the severe group plotted on the none/mild group at each time point for the subtalar, tibiotalar, tibiofibular, and talofibular. Correspondence particles with a pink outline indicates significant differences between the distance values of each of the two groups.