

Impact of Ligament Integrity on Trapeziometacarpal Joint Stability

Daniel Gordon¹, Lizzie Walker¹, Shuchun Sun¹, Jay Baek¹, Alexander Chiaramonti², Eugene Mah², Jacob Wolfe², Dale Daley², Hai Yao^{1,2}, Yongren Wu^{1,2}
¹Clemson University, ²Medical University of South Carolina
digordo@g.clemson.edu

Disclosures: Daniel Gordon(N), Lizzie Walker(N), Shuchun Sun(N), Jay Baek(N), Alexander Chiaramonti(N), Eugene Mah(N), Jacob Wolfe(N), Dan Daley(N), Hai Yao (N), Yongren Wu(N)

INTRODUCTION: The trapeziometacarpal (TMC) joint is the most common site of osteoarthritis (OA) in the upper limbs. This is primarily due to its saddle shaped geometry and synovial capsule structure, which allow articulation to occur with minimal bony stabilization. Surrounding ligaments, therefore, are essential to TMC stability, where the anterior oblique ligament (AOL) and dorsal radial ligament (DRL) play the most prominent role. To this end, there is controversy regarding whether the AOL or DRL provides the most support. Previous studies have noted that degeneration of the cartilage on the joint surface originates near the AOL insertion on the metacarpal. Moreover, our prior study showed that AOL tensile properties become significantly attenuated during OA progression. Accordingly, we hypothesize that AOL laxity or detachment may lead to joint instability. The objective of this study is to better understand the relationship between TMC ligament integrity and joint kinematics.

METHODS: 22 fresh-frozen cadaver hands (obtained from Science Care with institutional IRB approval) were x-rayed and diagnosed with an OA grade of 0-IV based on the Eaton-Littler grading scale by our clinical collaborators (A.C. and D.D.). They were then dissected, and the following musculotendon motor units were identified: Adductor Pollicis, Abductor Pollicis Brevis, Abductor Pollicis Longus, Flexor Pollicis Longus, Extensor Pollicis Longus, and Extensor Pollicis Brevis. The specimens were then categorized into the following groups: Young Healthy (age ≤ 45 , OA Grade \leq II), Old Healthy (age ≥ 45 , OA Grade \leq II), Unhealthy (any age, OA Grade $>$ II). The wrist and interphalangeal joints of the first three metacarpals were fused to maintain rigidity during the experiment. Custom designed and 3D printed optical-marker bases were rigidly attached to the trapezium, first metacarpal, and third metacarpal to aid motion tracking with the Motive Optitrack system as shown in Fig. 1. The musculotendon units were then attached to a novel designed dynamic muscle loading system capable of loading each muscle separately with a sensitivity of approximately 1N. A predefined muscle loading protocol, tuned to replicate common human hand tasks such as flexion, extension, adduction, abduction, and key pinch motions, was then executed while recording the motion. Following the experiment, each hand (with its marker bases still attached) was scanned using a clinical CT-scanner in order to reconstruct the three-dimensional bony geometry. The marker features retained in this reconstruction allowed for co-registration of the captured joint motion. Joint stability was evaluated using helical analysis (i.e., translations and rotations along the helical axis), as well as joint motion analysis (i.e., radial/ulnar, palmar/dorsal, and proximal/distal displacements of the metacarpal on the trapezium). The joint itself was then further dissected into palmar and dorsal aspects, where ligament/bony complexes could be identified for the AOL and DRL. Pull-to-failure mechanical tests were then performed to determine the AOL and DRL ligament tensile properties using a Bose ElectroForce dynamic mechanical testing instrument. Tensile data were represented in terms of a non-dimensional *ligament ratio*, which was calculated by dividing the AOL stiffness by the DRL stiffness.

RESULTS SECTION: A preliminary trend was observed in relating ligament mechanical properties with kinematic measures of joint stability. Joints with ligaments of similar stiffness between AOL and DRL (ratio close to 1) have been noted to have good stability based on the helical and joint motion analysis, where the measured translations and rotations generally exhibit the smaller variations in measurement. Conversely, ligament stiffness ratios far from unity show considerably larger variation. This trend can be seen in Fig. 2, where helical translation during abduction and extension, helical angle during abduction, and radial/ulnar rotation during abduction all showed small variability of joint instability near ligament ratios of 1; however, not all parameters studied followed this trend. Helical translation during key pinch, proximal/distal translation during flexion and radial/ulnar translation during extension were not sensitive to this analysis.

DISCUSSION: The trend seen with our data has been further explained in Fig. 3. When the ratio is near 1.0 (dark green region of Fig. 3), the AOL and DRL stiffness values keep the joint stable and prevent large rotations and translations. When the ratio is far from 1.0 (due to AOL stiffening with age or AOL degeneration due to wear and tear) the joint's ligament stabilizers are placed in an imbalance, leading to large joint instability (red region). However, for the region where the ligament properties differ, but the joint is still stable (light green), it could be due to the additional bony constraints created from osteophyte formations in the direction of articulation or flattened joint bony surface. Further joint surface congruence analysis and statistical correlation analysis with larger sample size are necessary to confirm this. Follow-up ligament mechanical testing on the same cohort of TMC specimens can also enable analysis of correlation between ligament mechanical performance and joint kinematics.

SIGNIFICANCE/CLINICAL RELEVANCE: Current method of TMC OA diagnosis uses x-ray and the Eaton-Littler scale which is mainly based on joint bony structure. Better understanding of the role of surrounding ligamentous tissue in OA progression could provide more scientific foundations to help develop strategies for early diagnosis and optimized intervention of TMC OA.

ACKNOWLEDGEMENTS: This work was supported by NIH/NIGMS COBRE: South Carolina Translational Research Improving Musculoskeletal Health (SC TRIMH; P20GM121342)

IMAGES AND TABLES:

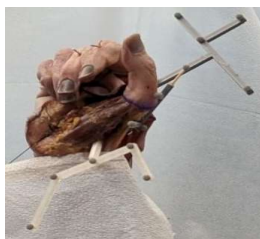

Figure 1: A photograph of one of the cadaver specimens with the marker bases attached.

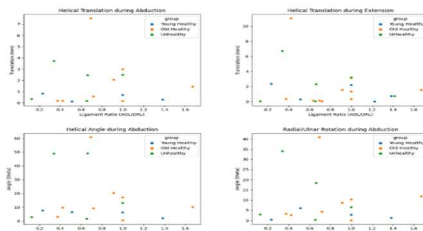


Figure 2: Representative data with the ligament ratio on the x-axis and measure of joint stability on the y-axis

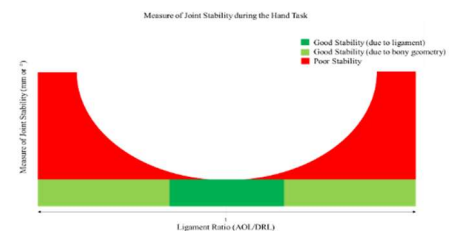


Figure 3: A schematic showing the prediction between the ligament ratio and joint stability. Areas of deep green are stable due to the ligament, while areas of light green are stable due to bony remodeling.