

The Efficacy of Endothelial Progenitor Cell Therapy Combined with Local Antibiotics in an Animal Model of Infected Non-Union

Ikran Ali¹, Stéphane Gagnon¹, Kalter Hali¹, Omar Hassan¹, Graeme Hoit², Emil Schemitsch³, Aaron Nauth¹

¹Keenan Research Centre for Biomedical Science, St. Michael's Hospital, Toronto, Canada

²University of Toronto, Division of Orthopaedics

³London Health Sciences Centre, London, Canada

Ikran.ali@mail.utoronto.ca

DISCLOSURES: I. Ali: None. S. Gagnon: None. K. Hali: None. O. Hassan: None. E. Schemitsch: None. A. Nauth: None

INTRODUCTION: Fracture non-unions caused by infection and critical sized bone defects remain a major challenge for orthopedic surgeons, often requiring multiple, complex surgeries to be performed in a staged fashion. Endothelial progenitor cells (EPCs) have been demonstrated to be a highly effective form of stem cell therapy for fracture healing and have been shown to possess immunogenic properties. However, the use of EPCs, in combination with local antibiotics (ABX) for the treatment of infected non-unions has not been investigated. This study aimed to assess the efficacy of EPC-based therapy +/- local ABX for the treatment of infected critical bone defects using an animal model. We hypothesized that EPC therapy would promote bone healing and eradicate infection, and that the addition of local antibiotics would further facilitate these outcomes.

METHODS: Fischer 344 inbred rats were anesthetized and received analgesics. The right femur was exposed, and a mid-diaphyseal osteotomy was created with an oscillating saw, forming a 5-mm segmental defect. The femur was stabilized with a mini-plate and screws. Subsequently, an inoculum of methicillin-sensitive *Staphylococcus epidermidis* was delivered at the defect site on a gelatin scaffold. Fourteen days later, after confirmation of infection, we applied one of the four following treatments creating a total of four groups; 1) Control (no treatment), 2) EPCs 3) EPCs + ABX (local vancomycin and rifampin) 4) ABX alone (local vancomycin and rifampin). The EPCs were isolated from the bone marrow of donor rats and cultured for eight days prior to implantation. Biweekly radiographs of the operated leg were taken to monitor bone healing progression and infection. All animals were euthanized 10 weeks after surgery. Four samples of soft tissue surrounding the fracture site and fixation material were collected and processed for microbiology. Radiographs were scored and assessed for union status, defect filling and infection. For union status, x-rays were classified as full-union or partial/non-union. For radiographic union scores animals were scored from 0-8. Radiographs were additionally assessed for radiographic signs of infection (no change, loosening of the hardware, presence of osteolysis, periosteal reaction away from the fracture site and fracture deformity). Bone healing was also assessed with micro-CT and biomechanics following specimen harvest. Continuous outcomes were compared between groups using one-way analysis of variance with post-hoc Tukey pairwise comparisons and binary outcomes were compared using Fisher's exact test. The primary outcome of this study was non-infected union (full union and negative culture). The differences in composite outcomes was analyzed using a Fisher's exact test, and a pairwise comparison with Bonferroni post-hoc adjustments (in order to achieve statistical significance in these pairwise comparison, a $p < 0.017$ was required).

RESULTS: The EPC+ABX or ABX alone groups demonstrated high rates of infection eradication (92% and 100% respectively) compared to the EPC only (42%) and Control (8%) groups (Table 1). The radiographic infection score for the Control group had significantly higher mean values (mean=2.8) compared to the EPC (mean=1.5), ABX (mean=1.8), and EPC+ABX (mean=0.8) groups. Full union rates were observed in 50% (6/12) of the animals in the EPC group, 0% (0/11) of the animals in the ABX group, 46% (6/13) of the animals that received EPC+ABX, and 0% (0/12) of the animals in the Control group (no treatment) (Table 1). The EPC group had significantly improved union rates compared to both the ABX and Control groups ($p < 0.05$), with no significant differences between the EPC+ABX and all other treatment groups. Animals treated with EPCs alone also had significantly higher radiographic union scores compared with the Control and ABX alone groups ($p < 0.05$), with no significant differences between other groups.

Micro-CT analysis showed that the EPC group had significantly higher bone volume and bone volume fraction compared to the ABX and Control groups ($p = 0.006$ and $p = 0.005$, respectively), but there were no differences between the EPC+ABX and all other treatments. Similarly, biomechanical analyses, demonstrated that the EPC group had a significantly higher torque compared to the ABX and Control groups ($p = 0.0050$) (Figure 1). There were no significant differences between any of the other groups. In terms of stiffness, the EPC group had a significantly higher stiffness compared to the Control group and the EPC+ABX had significantly higher stiffness compared to both the ABX and Control groups ($p < 0.05$) (Figure 2).

With respect to our primary outcome, the EPC+ABX group achieved the highest rate of non-infected union (46%), followed by the EPC group (33%), whereas no animals in the ABX group or Control group achieved this outcome. A post-hoc analysis test comparing rates of non-infected union showed that the EPC+ABX group had a significantly higher rate of non-infected union compared to ABX alone (0%) or Control group (0%) ($p = 0.003$). There was no significant difference between EPC+ABX (46%) and EPC (33%) ($p = 0.69$) or in comparing EPC to ABX and Control ($p = 0.09$) (Table 1).

DISCUSSION: These results demonstrate that the use of local ABX alone or in combination with EPCs is highly effective at eradicating infection in a preclinical model of infected nonunion. Additionally, the application of EPCs (EPC and EPC+ABX) significantly increases bone union rates (48% versus 0%) in this model. In the EPC+ABX group both union rates and infection rates were improved (resulting in the highest rate of non-infected union), pointing to EPC+ABX potentially being a superior therapy to EPC alone in the setting of infection. Our results suggest that this combination therapy has the potential to serve as an effective treatment for infected nonunions.

CLINICAL RELEVANCE: There is a crucial need to identify advanced therapies for the treatment of non-union and fracture-related infection. Our results show that the combination of EPCs and local ABX has the potential to be an effective single-stage treatment for infected non-unions.

	EPC (n=12)	ABX (n=11)	EPC + ABX (n=13)	Control (n=12)	p-value
Infection in Culture (%)	7 (58%)	0 (0%)	1 (8%)	11 (92%)	<0.001*
Union (%)	6 (50%)	0 (0%)	6 (46%)	0 (0%)	<0.001*
Non-Infected Union (%)	4 (33%)	0 (0%)	6 (46%)	0 (0%)	0.003***

Table 1: Results composite outcome (non-infected union), infection rates and union rates.

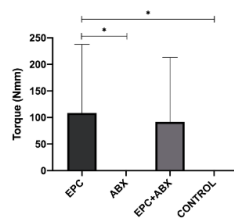


Figure 1: Graphical representation of max torque.

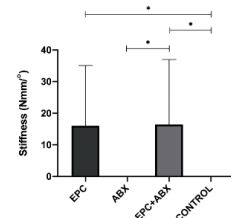


Figure 2: Graphical representation of stiffness.