

# Differences in Tibiofemoral Joint Space Width Distributions in Flexed vs. Extended Weight Bearing CT Scans

Connor Meng, Tyce C. Marquez, Shannon Ortiz, Brian Wolf, Donald D. Anderson

University of Iowa, Iowa City, Iowa  
mengconnor@gmail.com

**Disclosures:** Connor Meng (N), Tyce C. Marquez (N), Shannon Ortiz (N), Brian Wolf (1 – ConMed, 3B – ConMed), Donald D. Anderson (N)

**INTRODUCTION:** The load-bearing pose of the knee following anterior cruciate ligament reconstruction (ACLR) has been linked to early compositional MRI changes in cartilage consistent with post-traumatic osteoarthritis (PTOA).[1] This linkage was established using a specialty rig for imaging the loaded knee within an MRI system. Cone-beam CT enables functional weight bearing CT (WBCT) evaluation of the lower extremity amenable to detailed 3D joint space width (JSW) assessment, and it shows promise for detecting OA earlier than plain radiography.[2] WBCT also offers loaded knee pose information comparable or superior to MRI and could be more affordable/easier to collect across a broad network of clinical sites. 3D JSW distributions provide insight into both location/magnitude of joint space narrowing and indicators of altered joint positioning as might be expected in an over-constrained compartment from graft over-tensioning. These capabilities provide a means for quantifying joint alignment and how it changes with flexion, a direct indicator of knee joint laxity. Specifically, the screw-home mechanism (SHM – Figure 1) may cause 3D JSW distributions in the tibiofemoral joint to be different in flexed vs. extended poses. The aim of this study was to investigate differences in tibiofemoral JSW distributions in semi-flexed vs. extended WBCT scans.

**METHODS:** Forty-three subjects (age:  $21.4 \pm 8.2$  years, 17M/26F) with a unilateral isolated partial or complete ACL tear reconstructed by one of three surgeons were recruited to participate in this IRB-approved study. Thirty-seven bilateral semi-flexed ( $\sim 30^\circ$ ) and fifteen fully extended WBCT knee scans were acquired three months post-ACLR. 3D JSW maps and models of the tibiofemoral joint articulating surfaces were generated using a fully automated method.[3] For analysis of shifts in contact area with SHM, the center of contact (COC) in each compartment of the tibiofemoral joint was defined as the centroid of the lowest 10% of JSW values. Changes in the COC across these compartments for semi-flexed vs. extended scans were measured to assess the effect of the SHM.

**RESULTS:** In both the medial and lateral compartments of the tibiofemoral joint, the COC was more anterior in the extended than in the semi-flexed pose (Figure 2). The COC was more medial in the lateral compartment and more lateral in the medial compartment. Additionally, in ACLR knees, the average distance between the COC in semi-flexed vs. extended pose was larger than that of intact knees (medial:  $7.1 \pm 2.4$  vs  $6.1 \pm 2.3$ mm; lateral:  $6.7 \pm 2.9$  vs  $5.6 \pm 2.9$ mm). The COC was in a slightly more anterior position in ACLR knees than in intact knees.

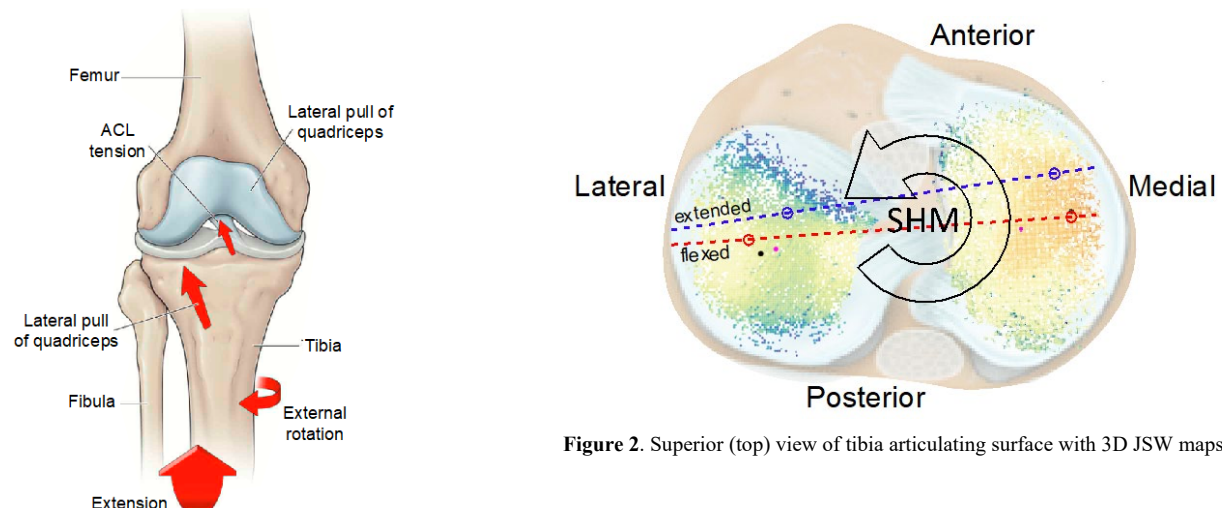
**DISCUSSION:** The difference in the location of the COC is consistent with external rotation of the tibia and ACL tensioning caused by the knee's SHM. During the knee SHM, the tibia rotates externally approximately  $15^\circ$ , causing anterior tibial glide on the medial compartment due to its longer articular surface [4]. While the current observed differences between intact vs. ACLR knees is interesting, these scans were acquired at an early follow-up time point and may simply show the influence of graft placement. Additional WBCT scans are being obtained at one-year post-ACLR, when any biomechanical changes associated with the surgery are more likely to be present. The current differences between intact vs. ACLR knees may be due to ACL tensioning during terminal extension or patient-specific joint geometry following surgery.

**SIGNIFICANCE/CLINICAL RELEVANCE:** Promising new biologics to prevent or mitigate PTOA risk in the knee are emerging, but clinical trials that can control for PTOA risk and detect outcome earlier are needed to enable timely study of new interventions. The establishment of new WBCT-based 3D imaging markers that reliably and affordably assess PTOA risk and detect degenerative joint changes earlier can facilitate more efficient clinical studies to proceed. This will lead to better-informed treatment decisions and provide a robust framework for the clinical testing of new treatments to prevent or forestall PTOA.

**REFERENCES:** [1] Lansdown DA, et al. J Orthop Res. (2020), 38(6):1289-95. [2] Segal NA, et al. Osteoarthritis Cartilage. (2023), 31(3):406-13. [3] McFadden EJ, et al. Osteoarthritis Cartilage. (2022), 30(S1):S284-5. [4] Kim HY, et al. Clin Orthop Surg. (2015), 7(3):303-9.

**ACKNOWLEDGEMENTS:** This research was supported by a grant from the Arthritis Foundation (Award #851789).

**IMAGES AND TABLES:**



**Figure 1.** The screw home mechanism (SHM) of the knee as it reaches full extension depends in part on tension in the ACL. [adapted from Musculoskeletal Key, Ch. 20 *The Knee*]

**Figure 2.** Superior (top) view of tibia articulating surface with 3D JSW maps