

# Complete Transphyseal, Partial Transphyseal, and Physeal-Sparing ACL Reconstruction Provides Similar Initial Joint Stability and Function in Early Juvenile Porcine Model

Yukun Zhang<sup>1,2</sup>, Kaan Gurbuz<sup>3</sup>, Jeffrey T. Spang<sup>2</sup>, Matthew B. Fisher<sup>1,2</sup>

<sup>1</sup>North Carolina State University, Raleigh, NC, <sup>2</sup>University of North Carolina at Chapel Hill, Chapel Hill, NC, <sup>3</sup>Kayseri State Education & Research Hospital, Kayseri, Turkey<sup>3</sup>

yzhan288@ncsu.edu

**Disclosures:** Yukun Zhang (N), Kaan Gurbuz (N), Matthew B. Fisher (N)

**INTRODUCTION:** The incidence of pediatric anterior cruciate ligament (ACL) injuries has been increasing [1]. Operative treatment becomes necessary in cases involving a meniscus tear or persistent instability after nonoperative treatment [2]. Current pediatric ACL reconstruction (ACLR) techniques include complete transphyseal, partial transphyseal, and physeal-sparing [3], with prior studies showing variable joint laxity, graft failure rates, and reoperation rates [4-6]. It is known that both the knee joint and the ACL change in terms of morphology and function with age [7,8]. Therefore, a model that accounts for age-specific ACL function is essential to directly compare ACLR techniques. Human pediatric joints for cadaveric testing are extremely limited, and animal models are often skeletally mature or the age is undefined. Current work aims to compare initial joint stability and function for complete transphyseal, partial transphyseal, and physeal-sparing ACL reconstruction within an early juvenile porcine model.

**METHODS:** Hind limbs were collected from 1.5 months old (early juvenile) pigs (n=6 per surgical technique). A robotic testing system with a universal force-moment sensor was used to test joint function (Kuka, simVITRO). The intact joint was first subjected to a 20 N anterior-posterior (AP) load and a 1 N·m varus-valgus (VV) torque at 60° of flexion. Kinematics were recorded, then repeated while recording forces for the intact joint, after capsule removal, and after ACL removal. ACL reconstruction (ACLR) was then performed [8], using a 1.5 month old porcine deep digital flexor tendon allograft with a single bundle technique. For each limb, one reconstruction technique (Fig. 1A) was performed through the tibial and femoral tunnels (6 mm diameter) placed between the anteromedial and posterolateral bundle footprints [9]. Femoral fixation was performed by a #2 FiberWire (Arthrex) with an ABS button (Arthrex), followed by 5 cycles of passive flexion-extension with 22 N pretension for preconditioning. Tibial fixation was then accomplished by a 11 mm x 20 mm staple (Arthrex) with 50 N pretension applied to the graft at maximum posterior translation at 40° of knee flexion. The same AP and VV loads were applied following ACLR. The recorded kinematics from both intact and ACLR states were replayed after removing the graft, followed by removal of the medial collateral ligament (MCL), lateral collateral ligament (LCL), medial meniscus (MMEN), and lateral meniscus (LMEN). Anterior-posterior tibial translation (APTT) under applied AP load and VV rotation under applied VV torques were calculated. The anterior force taken by ACL/graft and MCL under maximum anterior translation and the resultant forces of each tissue under maximum valgus and varus rotation were calculated. [11] One-way ANOVA with Tukey's HSD was utilized to compare joint laxity between different states as well as tissue force contribution between different surgical techniques. Significance was set at 0.05.

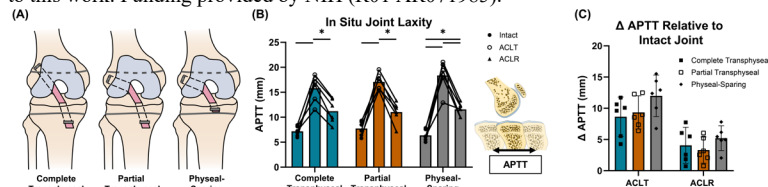
**RESULTS:** ACL transection (ACLT) resulted in destabilization in the joint under AP drawer (Fig. 1B) and VV torque (Fig. 2A). Complete transphyseal and partial transphyseal restored APTT to within 3.0 mm of the intact state, while APTT after physeal-sparing ACL reconstruction ( $11.0 \pm 2.1$  mm) was significantly greater than the intact state ( $6.4 \pm 1.1$  mm) ( $p=0.003$ ). Notably, all techniques restored VV laxity to within 2.7 degrees of the intact state (Fig. 2A). No significant differences in APTT (Fig. 1C) and VV (Fig. 2B) relative to intact state were observed between surgical techniques. Under anterior tibial loading, the anterior force carried by the graft decreased compared to the intact ACL with increased forces carried by the MCL (Fig. 3A). Under valgus rotation, resultant forces carried by the graft and MCL were higher, while those through the lateral meniscus decreased (Fig. 3B). Conversely, graft resultant force stayed under varus rotation, with increases in LCL and medial meniscus (Fig. 3C). No significant differences in resultant force were found between techniques.

**DISCUSSION:** Complete transphyseal, partial transphyseal, and physeal-sparing were similarly effective in the early juvenile porcine joint in terms of initial joint stability and function. Consistent with previous studies, early juvenile pigs led to large joint destabilization after ACL transection [9]. Unlike previous human studies that have found better post-operative AP laxity by physeal-sparing technique [5], our study revealed that the ability to restore APTT was similar across all surgical techniques at 60° of knee flexion. This difference may be impacted by the manner of testing: our study utilized porcine cadavers from early youth, whereas their work was from pediatric patients with a mean age much closer to adolescence (13.1 years). Though some of anterior forces in the current work shifted to MCL post-ACLR, the absolute load values were relatively low and similar between techniques. Given the youth of joints and grafts, loading conditions were relatively low to prevent tissue damage. Variations between states and techniques may become more pronounced with older joints and higher loads. Future work will assess how these surgical techniques impact joint stability and function in an early adolescent (4.5 months) porcine model.

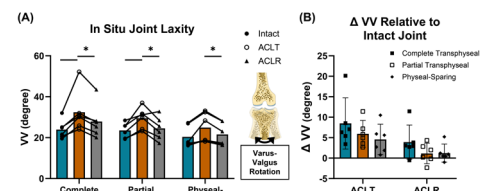
**SIGNIFICANCE/CLINICAL RELEVANCE:** Identifying the impact of different pediatric ACL reconstruction techniques on younger joints can lead to a better understanding of operative treatments for ACL injuries in young patients.

**REFERENCES:** [1] James EW et al., *Am J Sports Med*, 2021. [2] Ellis HB et al., *JBJS Rev*, 2023. [3] McConkey MO et al., *Curr Rev Musculoskelet Med*, 2011. [4] Cambers CC et al., *Am J Sports Med*, 2019. [5] Pagliuzzi G et al., *Knee Surg Sports Traumatol Arthrosc*, 2023. [6] Pierce TP et al., *Am J Sports Med*, 2017. [7] Cone SG et al., *J Orthop Res*, 2022. [8] Pradhan P et al., *Am J Sports Med*, 2023. [9] Howe D et al., *J Orthop Res*, 2022. [10] Kato Y et al., *Knee Surg Sports Traumatol Arthrosc*, 2009. [11] Howe D et al., *bioRxiv*, 2023

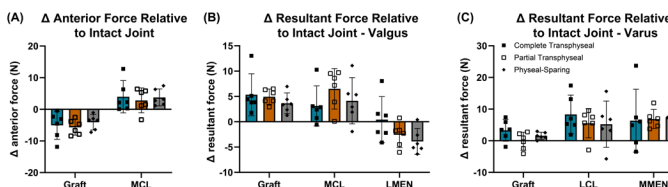
**ACKNOWLEDGEMENTS:** We would like to thank the NC State College of Veterinary Medicine and Laboratory Animal Resources for their contribution to this work. Funding provided by NIH (R01 AR071985).



**Fig. 1** Complete transphyseal, partial transphyseal, and physeal-sparing showed similar ability to restore initial joint stability after ACL reconstruction (ACLR) on 1.5 month old porcine knees. (A) Illustration of pediatric ACL reconstruction surgical techniques. (B) Anterior-posterior tibial translation (APTT) in response to anterior-posterior tibial load was compared between intact, ACL transected (ACLT), and ACLR states. (C) APTT increases relative to intact state were compared between different techniques under ACLT and ACLR states. Column and bar represent mean value with 95% confidence intervals. Statistical significance ( $p<0.05$ ) between states indicated (\*).



**Fig. 2** Surgical techniques showed similar ability to restore joint varus-valgus (VV) stability after ACL reconstruction (ACLR). (A) VV rotation in response to VV torque was compared across intact, ACL transected (ACLT), and ACLR states for different surgical techniques. (B) VV rotation increases relative to intact state were compared under ACLT and ACLR states. Column and bar represent mean value with 95% confidence intervals. Statistical significance ( $p<0.05$ ) between states indicated (\*).



**Fig. 3** Tissue function was similar across techniques. (A) Anterior force changes relative to intact state under maximum anterior translation were observed for reconstructed ACL graft and medial collateral ligament (MCL) for different surgical techniques. Resultant force changes relative to intact state were observed under (B) maximum varus rotation for graft, MCL, and lateral meniscus (LMEN) and (C) maximum varus rotation for graft, lateral collateral ligament (LCL), and medial meniscus (MMEN). Column and bar represent mean value with 95% confidence intervals.