

# The Potential of Using an Autogenous Tendon Graft by Injecting Bone Marrow Aspirate in a Rabbit Meniscectomy Model

Kazuya Nishino<sup>1</sup>, Yusuke Hashimoto<sup>1</sup>, Ken Iida<sup>1</sup>, and Hiroaki Nakamura<sup>1†</sup>

Department of Orthopaedic Surgery, Osaka Metropolitan University Graduate School of Medicine, Abenoku, Osaka 545-8585, Japan

Email of Presenting Author: kazuya\_best@hotmail.com

**Disclosures:** The authors declare no conflict of interest.

**INTRODUCTION:** Bone marrow aspirate (BMA) is an excellent source of cells and growth factors and has been used successfully for bone, cartilage, and soft-tissue healing. This study aimed to investigate the histological and biomechanical properties of autogenous tendon graft by injecting BMA and its protective effect against degenerative changes in a rabbit model of meniscal defects.

**METHODS:** All animal procedures were approved and conducted in accordance with the regulations of the University Committee on Animal Research (approval no. 11002). Adult white rabbits were divided into untreated, tendon, and tendon + BMA groups, and meniscal defects were created in the knees. The tendon graft and articular cartilage status were evaluated by macroscopic and histological analysis at 4, 12, and 24 weeks postoperatively among the three groups. The tendon graft in the tendon and tendon + BMA groups were used for biomechanical evaluation at 4, 12, and 24 weeks postoperatively. The meniscal covering ratio in the tendon + BMA group was better than that in the tendon and untreated groups at 12 and 24 weeks postoperatively. Statistical differences between groups were calculated using a one-way analysis of variance with a post hoc Student's t-test.  $p < 0.05$  was considered significant.

**RESULTS SECTION:** At 4 weeks postoperatively, the meniscus covering ratio was notably higher in both the tendon + BMA (0.50) and tendon (0.49) groups compared to the untreated group (0.13) with significant statistical differences ( $p < 0.0001$ ) (Figure 1). This trend continued at 12 and 24 weeks, with the tendon + BMA group showing a larger covering ratio than the other two groups. Histological examination of regenerated meniscus revealed fibrochondrogenesis in the tendon + BMA group at 4 weeks. At 12 and 24 weeks, the tendon + BMA group showed greater meniscus regeneration than the other groups, with significant histology scores. Moreover, positive safranin O staining was only seen in the tendon + BMA group at 12 and 24 weeks (Figure 2). Lastly, the amount of type II collagen, essential for cartilage structure, increased in the tendon + BMA group at 24 weeks.

The untreated group showed rapid degeneration of the femoral condylar cartilage, while the tendon and tendon + BMA groups had better preservation. Mankin scores, used to evaluate cartilage, were consistently lower in the tendon and tendon + BMA groups compared to the untreated group across the 4, 12, and 24-week marks. The tibial articular cartilage experienced more severe degeneration than the femoral one. At 12 weeks, the tendon + BMA and tendon groups had Mankin scores of 3.3 and 4.8, respectively, significantly lower than the untreated group's 6.8 ( $p < 0.0001$  and  $p < 0.0001$ , respectively). At 24 weeks, the Mankin score in the tendon + BMA group (average, 3.5) were lower than those in the tendon group (average, 4.9) and untreated group (average, 8.2) ( $p = 0.02$  and  $p < 0.0001$ , respectively).

**DISCUSSION:** Autologous BMA is simple for clinical use and can be prepared in one step during surgery. Known as a rich source of cells and growth factors, BMA aids in the healing of bone, cartilage, and soft tissue. In this study, the tendon + BMA group showed higher meniscus coverage and increased type II collagen at 12 and 24 weeks compared to the other groups. Various studies have demonstrated the effectiveness of BMA in healing acute total cartilage defects and improving the outcome of meniscus repair. Thus, BMA is expected to effectively promote the conversion of tendon to meniscus-like tissue. Our study has some limitations. First, the rabbit meniscus has greater spontaneous healing potential than the human meniscus; therefore, interspecies differences must be considered. Second, it is unclear how the BMA evolves in this setting. Third, we did not conduct quantitative assessments, statistical analysis, or grading scales in our detection of type II collagen via staining. In conclusion, transplantation of autogenous tendon grafts by injecting BMA improved the histologic score of the regenerated meniscal tissue and was more effective than the tendon and untreated group for preventing cartilage degeneration in a rabbit model of massive meniscal defects.

**SIGNIFICANCE/CLINICAL RELEVANCE:** (1-2 sentences): In this study, transplantation of an autogenous tendon graft by injecting BMA transformed into meniscus-like tissue. The tendon + BMA graft transplantation was effective in preventing cartilage degeneration in a rabbit model of massive meniscal defects.

## IMAGES AND TABLES:

Figure 1

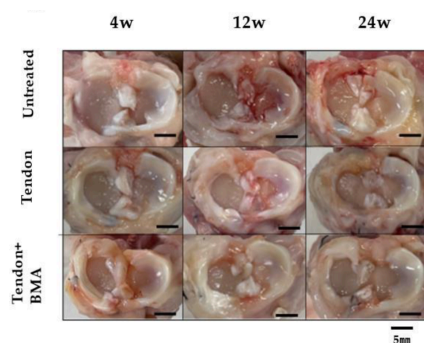


Figure 2

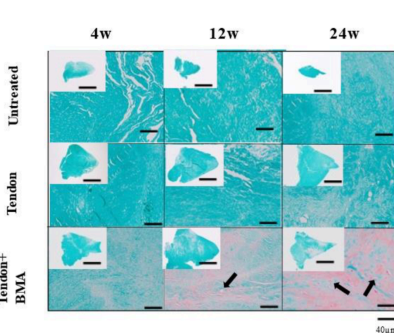


Figure 3

