

New shoulder brace for increasing glenohumeral abduction angle

Kiminori Yukata, Kenzo Fujii, Ryuuta Iwanaga, Atsushi Mihara, Tetsuya Seto, Kazuya Uehara, and Takashi Sakai
Department of Orthopedic Surgery, Yamaguchi University Graduate School of Medicine, Ube, Yamaguchi, Japan
+kyukata@yamaguchi-u.ac.jp

INTRODUCTION

Rotator cuff repair is an effective treatment for rotator cuff tears to restore shoulder function and alleviate pain. Despite the advancement and refinement of surgical techniques and implants such as suture anchors, re-tears often occur post-surgery. Hersche and Gerber highlighted an increase in passive tension within the supraspinatus following longstanding tendon rupture.[1] Similarly, Burkhart et al. demonstrated that physiologically simulated cyclic loading on the repair construct could result to gradual failure.[2] To address this, various types of orthoses are currently commercially available to maintain arm abduction and reduce tension in repaired upper rotator cuff tendons.

One such orthosis is a sling with the pillow. By placing the upper arm on the pillow, this orthosis aims to modify the angle between the upper arm and the trunk based on the pillow's size. As shoulder abduction involves both glenohumeral and scapulothoracic joint movements, it's challenging to ascertain how much of the glenohumeral joint is effectively supported by the abduction brace based solely on its appearance. Recently, Shimoe et al. introduced a dynamic X-ray method to separately capture the movements of the glenohumeral and scapulothoracic joints [3].

The objective of this study was to assess the glenohumeral abduction angle using X-rays while utilizing different braces. We conducted a retrospective comparison of the glenohumeral abduction (GH) angle and scapulothoracic upward rotation (ST) angle between the UltraSling IV AB™ with a large pillow (DJO Global, Lewisville, USA) and our newly developed shoulder abduction brace (GH abduction brace), following arthroscopic superior rotator cuff repair.

MATERIALS AND METHODS

Patients

Between September 2019 and March 2022, 39 arthroscopic superior rotator cuff repairs (39 patients) were performed in two hospitals. Twenty-five males and 14 females, average age: 63.8 years old (range: 47-77) were included in the present study. Average height and weight were 161.6 (range:143-177) cm and 62.8 (range: 44-94) kg, respectively. All patients kept the arm abducted using UltraSling IV AB™ (19 shoulders) or GH abduction brace (20 shoulders) for 6 weeks after surgery. Anteroposterior plain radiographs of the affected shoulder joint in the frontal plane were taken in neutral position before surgery, and in the abduction position with brace at 1 week after surgery. This retrospective study was approved by the hospital ethical committees.

Measurements

All measurements were performed by using the Synapse PACS software (Fujifilm, Tokyo, Japan). The measurement precision was set at 1 degree. Magnification, contrast and enhancement with monochrome inversion were used for better visualization of bones on radiograms. We drew 3 lines on the X-ray (Fig. 1). The first was a line connecting the lateral margin of the third rib with the lateral margin of the sixth rib (reference line). The second was a line connecting the superior and inferior ends of the scapular fossa (scapular articular surface). The third is bony axis of the humerus. ST was defined by the angle between the second line and the reference line. GH was defined by the angle between the scapular articular surface and the humeral axis. The difference between pre-surgery neutral and postoperative shoulder abducted positions was calculated and defined as Δ GH and Δ ST, respectively (Fig. 1).

Data analysis

Data were represented as mean \pm standard deviation (SD). Differences between two orthoses were analyzed using Student *t*-tests. P values <0.05 was statistically significant.

RESULTS

There was no statistically significant difference observed between two shoulder braces concerning age, height, and weight. In GH abduction brace, Δ GH and Δ ST were recorded as $32.8^\circ \pm 8.6^\circ$ and $4.8^\circ \pm 6.0^\circ$ respectively. In contrast, the UltraSling IV AB™ exhibited corresponding values of $14.8^\circ \pm 6.4^\circ$ for Δ GH and $13.9^\circ \pm 6.5^\circ$ for Δ ST

(Fig. 3B). Notably, the glenohumeral abduction angle showed a significant increase in GH abduction brace compared to UltraSling IV AB™ ($p<0.05$).

DISCUSSION

The current study demonstrated that newly developed GH abduction brace resulted in a greater glenohumeral abduction angle, but also led to a decrease in scapulothoracic upward rotation angle. Hawthorne et al. reported an average glenohumeral abduction angle of 25° for the UltraSling™ in healthy adults.[4] However, our results indicated smaller angles compared to their findings. This observed difference could potentially be attributed to variations in X-ray imaging and measurement methodologies. Several clinical studies have reported a correlation between higher intraoperative higher tension is linked to a higher risk of re-tear. Based on biomechanical perspectives, the amount of tension measured on the rotator cuff tendons is influenced by the position of the shoulder. Hatakeyama et al. described that the strain in the sagittal, scapular and coronal planes significantly decreased when the arm was elevated more than 30 degrees after the repair of medium-sized rotator cuff tear.[5] These investigations suggested that controlled tension reduction through immobilization in the shoulder abduction position could be advantageous for the healing of the rotator cuff tendon. In summary, a sling with the pillow could alleviate tension on the repaired superior rotator cuff tendons. Nevertheless, their effects might be substantial than initially anticipated. Our newly developed GH abduction brace has shown improvements in glenohumeral abduction angle. To ascertain whether this new brace effectively reduces the incidence of retears, further comprehensive studies are warranted.

SIGNIFICANCE/CLINICAL RELEVANCE

The newly created orthosis would be expected to prevent rotator cuff re-tear and displacement of the greater tuberosity fracture caused by reducing tension on the superior rotator cuff.

REFERENCE

- [1] Hersche and Gerber. J Shoulder Elbow Surg. 7:393-396, 1998
- [2] Burkhart, et al. Arthroscopy. 13(2):172-176,1997
- [3] Shimoe, et al. J Orthop Sci. 22(5):840-845, 2017
- [4] Hawthorne, et al. HSS J. 14(2):114-122, 2017
- [5] Hatakeyama, et al. Am J Sports Med. 29(6):788-794, 2001

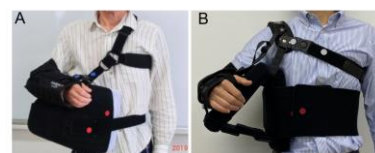


Figure 1. (A) UltraSling IV AB™, (B) GH abduction brace

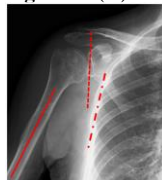

Figure 2. Dashed line: reference line, dotted line: scapular articular surface, solid line: humeral axis

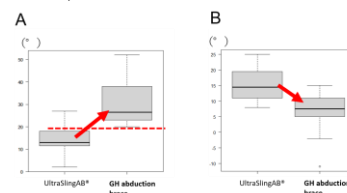


Figure 3. (A) Glenohumeral abduction angle, (B) Scapulothoracic upward rotation angle