

Capsular Repair Location Significantly Affects Humeral Head Centering and Maximal Anterior Translation after Distal Tibial Allograft Reconstruction in a Glenoid Bone Loss Model

Amirhossein Jahandar¹, Matthew Fury², Carl Cirino², Lawrence Gulotta², David Dines², Joshua Dines², Michael Fu², Theodore Blaine², Samuel Taylor², Andreas Kontaxis¹

¹Hospital for Special Surgery Biomechanics Department, New York, NY, ²Hospital for Special Surgery Sports Medicine Institute, New York, NY
Jahandara@hss.edu

Disclosures: Jahandar (N), Fury (N), Cirino (N), Kontaxis (N), Gulotta (Exactech, Smith & Nephew, Zimmer Biomet), Dines (Zimmer Biomet), Dines (Arthrex, ConMed Linvatec), Fu (N), Blaine (Lima Corporate, Stryker Corporation, Zimmer Biomet), Taylor (DJO, Mediflix).

INTRODUCTION: There is increasing interest and utilization of distal tibial allograft reconstruction (DTA) to restore glenohumeral stability in the setting of critical glenoid bone loss.¹ Surgical techniques describe varying methods of concomitant capsular repair following DTA without clinical or biomechanical data to support their techniques. The purpose of this study is to evaluate the effect of capsular repair location on humeral head translations in a glenoid bone loss model and DTA reconstruction.

METHODS: Nine human cadaveric specimens (mean age: 62.2, range 57-69; 87.5% male) were dissected and mounted on a custom shoulder table that provides 6 degrees of freedom at the glenohumeral joint. The specimens were placed in 60° of glenohumeral abduction and the rotator cuff tendons were loaded to create a compression (Supraspinatus 2lbs, Infraspinatus 3lbs, Teres minor 1lbs, Subscapularis 4 lbs). An anterior glenohumeral force was progressively applied (rate of pull 1mm/sec) and up to 40N through the pectoralis tendon and with the humerus at neutral rotation. A camera motion system was used to measure the gleno-humeral translations.

A 25% bone loss model was created by removing anterior glenoid bone. A DTA graft that was measured and trimmed to match the removed glenoid bone was used to restore 100% of the native glenoid width. The following conditions were tested: 1. intact, 2. Bankart lesion, 3. bone loss model with DTA reconstruction but no capsular repair (DTA), 4. DTA with capsulolabral tissues repaired to the graft (DTA_Graft), and 5. DTA with capsulolabral tissues repaired to the glenoid graft interface (DTA_Glenoid). A repeated measures ANOVA was performed to determine if there was a significant difference in maximum anterior translation between the capsular repair conditions.

RESULTS SECTION: All DTA reconstructions resulted in reduced maximum anterior translation compared to the Bankart lesion ($p=0.001$, $p=0.001$, $p=0.001$ for DTA, DTA_Graft, DTA_Glenoid respectively). However, when the capsular repair was performed to the glenoid graft interface (DTA_Glenoid) it resulted in the most restrictive anterior translations of all the DTA reconstructions ($0.8\pm3.5\text{mm}$, $p=0.05$ vs DTA and $p=0.038$ vs DTA_Graft). The DTA_Glenoid repair also resulted in the most posterior humeral resting position compared to all other conditions ($p<0.045$ for all comparisons).

DISCUSSION: When performing a distal tibial allograft reconstruction with capsular repair to the native glenoid it can result in over constraining the glenohumeral joint for both resting position and maximum anterior translation during time zero biomechanical testing. DTA without capsular repair and DTA with capsular repair to the graft restore the resting position while providing dynamic glenohumeral anterior stability.

SIGNIFICANCE/CLINICAL RELEVANCE: The DTA demonstrated clear benefits for restoring glenohumeral anterior stability to patients with anterior glenoid bone loss. However, when combined with capsule repair between the graft and the glenoid it can cause posterior humeral shift and constrain anterior translation significantly less than intact.

REFERENCES: 1. Provencher MT et al. Anatomic osteochondral glenoid reconstruction for recurrent glenohumeral instability with glenoid deficiency using a distal tibia allograft. Arthroscopy. 2009

ACKNOWLEDGEMENTS: No Acknowledgements

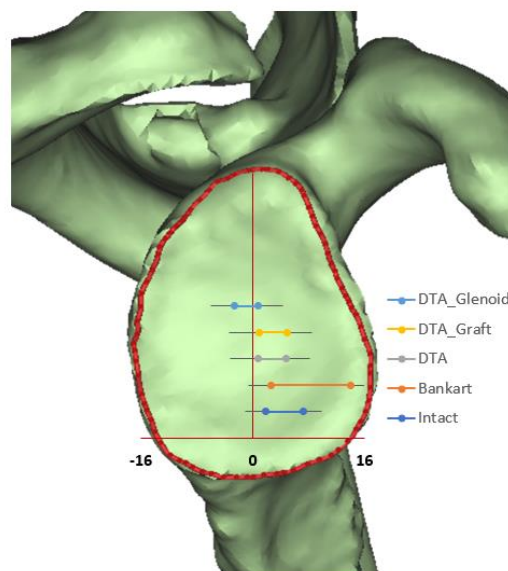


Figure 1: The results show the maximum anterior humeral translations following the application of anterior force.