

Healing Of Partial-Thickness Cartilage Injuries in the Immature Skeleton: Development of a Large Animal Model for Pediatric Cartilage Research

Brendan D. Stoeckl^{1,2}, Elisabeth A. Lemmon^{1,2}, Jie C. Nguyen^{1,3}, Bijan Dehghani^{1,2}, Vandan Patel³, Carlos Yaya³, Robert L. Mauck^{1,2}, Theodore J. Ganley^{1,3}, Soroush Baghdadi³

[1] University of Pennsylvania, Philadelphia PA [2] CMC VA Medical Center, Philadelphia, PA. [3] Children's Hospital of Philadelphia, Philadelphia PA

bstoeckl@pennmedicine.upenn.edu **Disclosures:** TJG 8—American Journal of Sports Medicine, RLM 8—JOR Spine

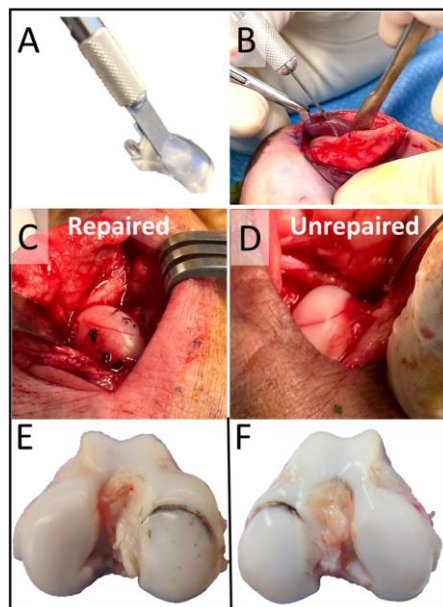


Figure 1: A) 3D printed alignment jig and square blade used to create standardized femoral condyle defects. B) Jig in use intraoperatively. C) Medial femoral condyle defect after suture repair and D) Defect left unrepaired. E) Representative India Ink staining highlighting defect border after 6 weeks in vivo in a repaired specimen and an F) unrepaired specimen.

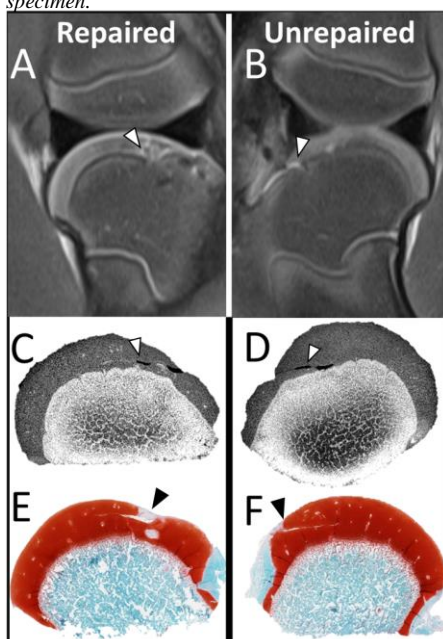


Figure 2: Representative MRI images, contrast enhanced μ CT, and Safranin O-Fast Green stained osteochondral histology of repaired (A, C, E) and unrepaired (B, D, F) specimens. Arrows emphasize residual cartilage gap.

INTRODUCTION: Injuries to immature articular cartilage are uncommon in the pediatric population but can be a precursor to osteoarthritis and growth disturbance if not managed appropriately. Previous research on this topic has been limited to retrospective clinical cohorts, partly due to the lack of a reliable model for pediatric cartilage research. This study aimed to develop a large animal model for *in vivo* pediatric cartilage research by evaluating the healing potential of cartilage injuries in the developing knee.

METHODS: Four 6-week-old Yucatan minipigs were utilized in this study, and all animal procedures were performed with IACUC approval. Under general anesthesia, a medial parapatellar arthrotomy was performed bilaterally to gain access to the medial femoral condyles. An 8mm-wide blade was guided by a 3D-printed jig to make a standardized cartilage defect on the weight-bearing surface of each medial femoral condyle at a 45-degree angle to the shaft of the femur (**Fig 1A-B**). For each animal, one flap was repaired with suture (**Fig 1C**), and the contralateral side left unrepaired (**Fig 1D**), and the knees were closed in layers in the usual fashion. Animals were euthanized 6 weeks post-operatively. Knees underwent MRI imaging, followed by dissection and gross assessment with India Ink staining to highlight areas of worn cartilage. Indentation creep tests were performed, both within and adjacent to each defect site, and the resulting deformation curves were fitted to a model that outputs compressive and tensile moduli and permeability. Condyles were then assessed via microCT after immersion in Lugol's solution (I_2 and KI in water) to enhance cartilage radiopacity, and histologically with Safranin-O/Fast Green staining. Comparisons were made between repaired and unrepaired specimens.

RESULTS: On gross examination (**Fig 1E-F**), all flaps were stable, except for one unrepaired specimen where the flap detached and became an intra-articular cartilage fragment. On gross inspection, the cartilage injury was readily apparent as highlighted by India Ink staining. MRI examination showed normal cartilage signal intensity with varying degrees of subchondral marrow edema and localized endochondral ossification dysfunction. (**Fig 2A-B**) Contrast enhanced microCT showed a residual gap in all lesions (**Fig 2C-D**). Histologic examination confirmed these residual incisional gaps, with evidence of tissue bridging on the superficial edge of each defect and varying degrees of proteoglycan depletion (**Fig 2E-F**). With the exception of tensile modulus on the unrepaired side, there was a trend towards a reduction in cartilage moduli, and an increase in cartilage permeability, in the defect site in comparison to adjacent tissue, with no apparent difference between repaired and unrepaired specimens (**Fig 3**).

DISCUSSION: Young Yucatan minipigs can be used as an *in vivo* pediatric cartilage surgical defect model. The thick articular cartilage allows for the creation of partial- and full-thickness cartilage defects in a standardized manner and for clinically relevant repair. Clinically relevant MRI is feasible, and microCT, histology, and biomechanical tests allow for thorough assessment of tissue microstructure and quality. Our preliminary data on cartilage injury and repair suggests some healing potential, but with altered imaging and biomechanical properties. At this early (six week) timepoint, suture repair did not appear to result in superior healing when compared to defects left unrepaired, however it did prevent progression to a loose cartilage fragment. Future studies will focus on longer term timepoints to assess healing potential and growth alterations.

SIGNIFICANCE: In this study, we developed an *in vivo* standardized surgical model for pediatric cartilage injury and repair that is safe, feasible, and easily reproducible, and can serve as a test bed to assess pediatric cartilage repair strategies.

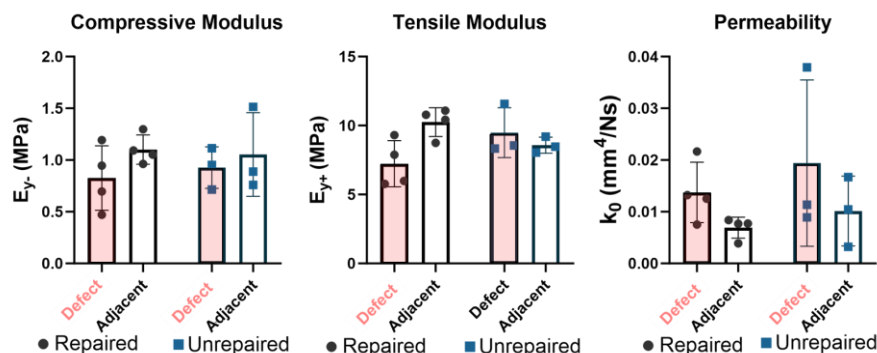


Figure 3: Compressive modulus, tensile modulus, and permeability as measured through creep indentation tests. Tests were performed in the middle of and adjacent to the defect created in each medial femoral condyle.

