

The Yucatan Minipig as a Potential Preclinical Animal Model for Carpal Bone Arthroplasty

Quianna M. Vaughan¹, Sophia Sordilla¹, Amy Morton¹, Douglas C. Moore¹, Edward Akelman¹, Joseph J. Crisco¹
¹Department of Orthopaedics, Warren Alpert Medical School of Brown University and Rhode Island Hospital, Providence, RI
Email: quianna_vaughan@brown.edu

Disclosures: Q.M. Vaughan: None. S. Sordilla: None. A.M. Morton: None. D.C. Moore: None. E. Akelman: None J.J. Crisco: None.

INTRODUCTION: Hand and upper extremity injuries are a large contribution to common orthopedic injuries and often lead to painful osteoarthritis and disability which minimizes quality of life. Patients who suffer from wrist injuries, namely fractures, carpal instability, and ligament injury, commonly develop severe osteoarthritis (OA). The successful treatments and outcomes for injuries to the hip, knee, and shoulder are attributed to the evaluation of extensive *in vitro* and *in vivo* studies, as compared to the wrist. As a result, the development of innovative therapeutics for carpal OA has been hindered due to a lack of data and an insufficient understanding of the anatomical and biomechanical complexity of the wrist. Our overall goal is to establish the Yucatan minipig as a preclinical animal model to aid in the development and validation of innovative therapeutics and hemiarthroplasties to treat carpal bone pathologies associated with ligament injuries and severe OA. The Yucatan minipig carpus is a potential preclinical animal model for the human carpus because of the similarities in size, anatomy, bone, and cartilage physiology (Fig. 1). In a previous study, the radial carpal bone (RCB) was used as a model for scaphoid nonunion due to the location of the bone and analogous nutrient vessels into the dorsal and volar poles of the RCB that are similar to the scaphoid in humans [1]. Our specific aim is to quantitatively analyze the morphology of the RCB to determine the feasibility of employing specimen weight as a predictive measure for RCB size to assist in the selection of a carpal bone arthroplasty with optimal dimensions for successful implantation in *in vivo* studies.

METHODS: A total of 22 Yucatan forelimbs (18-20 months in age), 8 females and 3 males ranging between 49-61 kg in weight, were imaged with a clinical CT scanner to establish our porcine database. A total of 11 RCBs were resected from this specimen group and scanned using a MicroCT40 desktop microcomputed tomography (μ CT) system (Scanco Medical, Brüttisellen, CH). The system was set to 70KVp and 114 μ A, and an isometric voxel size of 30 μ m. The clinical CT-scanned RCBs were segmented using Mimicsv22 (Materialise, Leuven, Belgium) and exported as triangular surface models. The subchondral bone and articular cartilage were segmented from μ CT-scanned RCBs. The inertial coordinate system (ICS) was calculated for each clinical CT model using custom MATLAB scripts (Mathworks, US) assuming uniform density and using geometric mean to define the ICS centroid. Anatomical specificity and sign of the computed ICS vectors were standardized to orient dorsal, proximal, and ulnar (facing the intermediate carpal bone). Bone models were imported to Geomagic Wrap (Geomagic Wrap; 3D Systems, SC) to smooth the surface of the RCB and compute bone volume, surface area, and bounding box dimensions. Articular cartilage thickness was defined as the distance between the articular cartilage and subchondral bone meshes (Fig 2). Mean articular cartilage thickness and standard deviation were calculated for each bone. Mean articular cartilage thickness was averaged across the 11 collected RCBs. Linear regression was used to determine correlations between specimen weight and bone volume, and specimen weight and bounding box dimensions.

RESULTS: The average RCB volume was $1570.7 \pm 182.4 \text{ mm}^3$ with an average surface area of $789.9 \pm 60.9 \text{ mm}^2$. The bounding box dimensions had an average length of $19.6 \pm 0.9 \text{ mm}$ in the volar-dorsal direction (x), $16.1 \pm 0.7 \text{ mm}$ in the proximal-distal direction (y), and $11.4 \pm 0.8 \text{ mm}$ in the radial-ulnar direction (z). A significant correlation existed between specimen weight and bone volume, specimen weight and bone length in the volar dorsal direction, and specimen weight and bone length in the radial-ulnar direction ($p < 0.0001$, $R^2 = 0.724, 0.593, 0.560$, respectively). In the proximal-distal direction, the relationship between specimen weight and bone length exhibited an R^2 value of 0.265 and a p-value of 0.0169. The mean articular cartilage thickness across RCBs for the distal facet was $0.3 \pm 0.03 \text{ mm}$, while the proximal facet displayed a mean articular cartilage thickness of $0.3 \pm 0.04 \text{ mm}$. The articular cartilage thickness across all RCBs spanned a range from 0.24 to 0.38 mm.

DISCUSSION: Our specific aim was to analyze the morphology of the RCB to determine if specimen weight can be used as a predictive measure for RCB size. We found a modest correlation between specimen weight and bone volume, and specimen weight and bounding box dimensions. However, the correlations support specimen weight as an indicator of the approximate range of viable implant sizes. Comparing averaged bone volumes of the minipig RCB ($1570.7 \pm 182.4 \text{ mm}^3$) to averaged volume of the human scaphoid ($2390.1 \pm 673.6 \text{ mm}^3$) [2], the human scaphoid is consistently larger. A limitation of this study includes the effect CT resolution may have on bone volume and bounding box dimensions. Another limitation of this study is all specimens were skeletally immature, and once the Yucatan minipig is matured, the specimen weight may continue to increase while the bone volume remains consistent. A final limitation of this study is the small sample size of our Yucatan minipig database.

SIGNIFICANCE: The establishment of a preclinical animal model for the human wrist will advance therapeutics aimed at restoring normal carpal biomechanics and mitigating the progression of osteoarthritis, which will contribute to the data-driven development of human carpal bone arthroplasty.

ACKNOWLEDGEMENT: Supported in part by NIH/NIAMS under award number R21AR082130.

REFERENCES: [1] Behrends, *J Funct Biomater*, 2015. [2] Crisco, *J Hand Surg*, 2005.

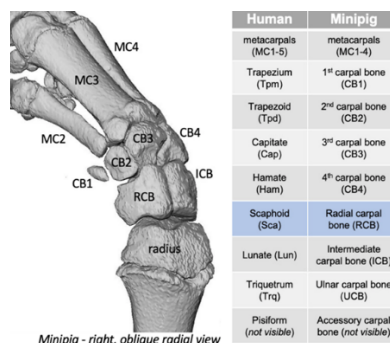


Figure 1. Bone model segmentation of the Yucatan minipig forelimb CT. Table of Yucatan minipig and human bone analogs.

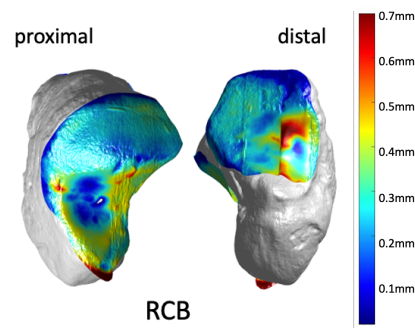


Figure 2. Thickness of articular cartilage indicated by a colormap for the radial articulating facet (left) and distal carpal row articulating facet (right) of an RCB.