

Tilt of the Tibial Component in the Coronal Plane During Walking in KA-TKA Compared to MA-TKA

Takahiro Arakawa¹, Kenichi Kono¹, Tetsuya Tomita², Takaharu Yamazaki³, Masashi Tamaki⁴, Shoji Konda⁴, Teruya Ishibashi⁴, Ryota Yamagami¹, Kohei Kawaguchi¹, Tomofumi Kage¹, Ryo Murakami¹, Hiroshi Inui⁵, Shuji Taketomi¹, Sakae Tanaka¹

¹The University of Tokyo, Tokyo, Japan, ²Morinomiya University of Medical Science, Osaka, Japan, ³Saitama Institute of Technology, Saitama, Japan, ⁴Osaka University, Osaka, Japan, ⁵Saitama Medical Center, Saitama, Japan
d03sm003@gmail.com

Disclosures: Takahiro Arakawa (N), Kenichi Kono (N), Tetsuya Tomita (N), Takaharu Yamazaki (N), Ryota Yamagami (N), Kohei Kawaguchi (N), Tomofumi Kage (N), Ryo Murakami (N), Hiroshi Inui (N), Shuji Taketomi (N), Sakae Tanaka (N)

INTRODUCTION: The tilt in the coronal plane of the proximal tibial articular surface is reported to be parallel to the ground and perpendicular to the weight-bearing axis of the limb during bipedal walking [1]. The proximal joint surface of the tibia is varus to its mechanical axis by an average of 3 degrees, which is thought to keep joint surface parallel to the ground in the coronal plane while the tibial axis is varus to the body axis during stance phase in bipedal walking. In total knee arthroplasty (TKA), the mechanical alignment (MA) method, in which the tibial component is placed perpendicular to the tibial axis in the coronal plane without considering native varus, has been the standard. However, the concept of kinematic alignment (KA), which aims to reproduce the original varus tibial joint surface, has recently emerged [2]. According to this logic, the tibial component should be parallel to the ground in the coronal plane during walking in KA-TKA, whereas few studies have undertaken its validation. The purpose of this study is to evaluate the coronal tilt of the tibial component during walking in KA-TKA compared to MA-TKA.

METHODS: A total of 15 KA-TKA knees in 11 patients and 14 MA-TKA knees in 10 patients were investigated. All surgeries were performed with computer navigation. The proximal tibial osteotomy was executed perpendicularly in the coronal plane to the mechanical axis in MA-TKA and was restricted to a maximum of 3 degrees of varus in KA-TKA. Each patient underwent postoperative treadmill walking, and fluoroscopic kinematic analysis was conducted using the 2D3D registration technique [3]. The horizontal plane was defined by positioning a metal plate with a flatness of 0.03/100 mm horizontally, using a leveler with a sensitivity of 0.02 degrees and an accuracy of ± 0.06 degrees [4]. Trends in the coronal tilt of the tibial component (TC) during the stance phase were examined (Fig. 1). Varus was designated as positive, and valgus as negative. Repeated measures of analysis of variance were employed to assess the differences between KA-TKA and MA-TKA.

RESULTS SECTION: The medial proximal tibial angle was 86.6 ± 1.0 degrees in KA-TKA and 89.7 ± 0.7 degrees in MA-TKA, respectively. The coronal tilt of the TC at heel strike was 1.6 ± 2.1 degrees in the KA group and -3.1 ± 2.5 degrees in the MA group. These values were -1.2 ± 2.2 degrees and -4.8 ± 2.2 degrees at mid-stance and 1.5 ± 3.2 degrees and -3.8 ± 3.0 degrees at toe off, respectively (Fig. 2). In both groups, the TC transitioned to valgus from heel strike to mid-stance and to varus from mid-stance to toe off. The mean tilt during the stance phase was derived through integration: -0.3 degrees in the KA group and -4.3 degrees in the MA group. The TC exhibited significant valgus orientation throughout the stance phase in MA-TKA.

DISCUSSION: The most important finding of this study is that the coronal tilt of the TC during the stance phase was more closely aligned with the horizontal plane in KA-TKA compared to MA-TKA. While placing the TC perpendicular to the tibial mechanical axis in the coronal plane has traditionally been viewed as mechanically advantageous, it was demonstrated that the TC exhibited valgus alignment to the horizontal plane in MA-TKA during the stance phase of in vivo gait. The direction of the load on the TC is not precisely perpendicular to the horizontal plane due to dynamic factors and the position of the upper body's center of gravity. Nevertheless, identifying the absolute tilt of the TC may provide insight into whether KA-TKA or MA-TKA holds a mechanical advantage with respect to polyethylene wear and stress distribution on the bone-implant interface.

SIGNIFICANCE/CLINICAL RELEVANCE: The coronal tilt of the TC during the stance phase was more closely aligned with the horizontal plane in KA-TKA than in MA-TKA. This finding possibly clarifies whether KA-TKA or MA-TKA is mechanically more advantageous.

REFERENCES: [1] Victor JMK, Bassens D, Bellemans J, Gürsu S, Dhollander AAM, Verdonk PCM. "Constitutional varus does not affect joint line orientation in the coronal plane," *Clin. Orthop. Relat. Res.*, 472(1), 98–104, 2014.
[2] Howell SM, Kuznik K, Hull ML, Siston RA. "Results of an initial experience with custom-fit positioning total knee arthroplasty in a series of 48 patients," *Orthopedics*, 31(9), 857–863, 2008.
[3] Yamazaki T, Watanabe T, Nakajima Y, Sugamoto K, Tomita T, Yoshikawa H, Tamura S. "Improvement of depth position in 2-D/3-D registration of knee implants using single-plane fluoroscopy," *IEEE Trans. Med. Imag.*, 23(5), 602–612, 2004.
[4] Takahiro A, Kono K, Tetsuya T, Takaharu Y, Ryota Y, Kohei K, Tomofumi K, Ryo M, Hiroshi I, Shuji T, Sakae T. "Verification of Horizontal Plane Measurement Method in Fluoroscopy" presented at the Orthopaedic Research Society 2023 Annual Meeting, Dallas, Texas, US, Feb. 10-14, 2023.

IMAGES AND TABLES:

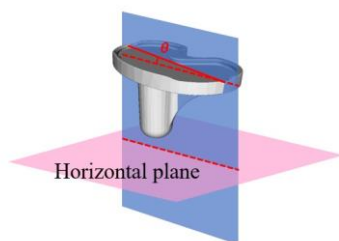


Fig. 1. The coronal tilt of the tibial component to the horizontal plane (θ) was measured.

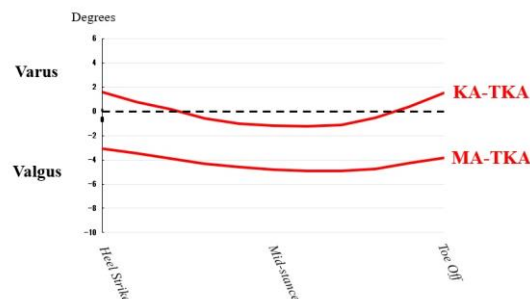


Fig. 2. Trends in the coronal tilt of the tibial component during the stance phase. Dotted lines indicate horizontal.