

Imaging evaluation of trunk muscles and periprosthetic hip muscles in patients with osteonecrosis of the femoral head

Hironori Yamane¹, Hyonmin Choe¹, Koki Abe¹, Hiroyuki Ike¹, Masashi Shimoda¹, Yutaka Inaba¹
¹Yokohama City University Department of Orthopedic Surgery
Email: t236074g@yokohama-cu.ac.jp

Disclosures: None

INTRODUCTION: Osteonecrosis of the femoral head (ONFH) often presents with underlying disease compared to osteoarthritis of the hip. ONFH with underlying disease can be associated with unfavorable outcomes following total hip arthroplasty (THA). The purpose of this study is to investigate the effects of disuse and underlying conditions associated with ONFH on the muscles of the trunk and the periprosthetic hip muscles.

METHODS: This retrospective study included 20 patients who were diagnosed with unilateral non-traumatic ONFH and underwent femoral osteotomy or primary THA in our institution between June 2019 and December 2022. Muscle analysis was performed using preoperative CT (computed tomography) imaging by measuring the volume and the mean CT value in Hounsfield units (HU) of posterior trunk muscles, iliopsoas, iliacus, psoas major and minor, gluteus maximus, gluteus medius, and gluteus minimus. The quantitative assessment of the muscle volume and CT value was conducted using the open-source software 3D Slicer to construct three-dimensional images (Figure 1, 2). Age, body mass index (BMI), corticosteroids, alcohol and underlying health conditions were reviewed. All statistical analyses were conducted in JMP17 with P-value of 0.05 as threshold for statistical significance.

RESULTS: Twenty patients including 10 males and 10 females are included in this study. On average, patients are 49.2 ± 16.0 years old with BMI $23.9 \pm 5.6 \text{ kg/m}^2$. Seven patients were diagnosed with steroid-associated ONFH, and 6 patients were diagnosed with alcohol-associated ONFH. Underlying disease included acute lymphoblastic lymphoma and dermatomyositis in each 2 patients, SLE, interstitial pneumonia, and COVID-19 in each 1 patient. According to the CT imaging 3D analysis, muscle volume of the iliopsoas, psoas major and minor, gluteus maximus and gluteus minimus on the affected side were significantly lower than those on the contralateral side in unilateral ONFH patients ($P < 0.05$, respectively). In addition, the mean CT value of the iliopsoas, psoas major and minor, gluteus maximus, gluteus medius, and gluteus minimus on the affected side were significantly lower than the contralateral side ($P < 0.05$). Despite these significant difference in muscles around hip joint, no significant difference was observed in the trunk muscles between affected and contralateral side.

DISCUSSION: In this study, iliopsoas muscles and gluteus muscles on affected side were determined to have significantly lower muscle volume and CT value than contralateral side in ONFH patients. However, the muscle volume and CT value of the posterior trunk did not reach the statistical significance between affected side and the contralateral side. This discrepancy may be due to the trunk muscle is maintained with disuse of affected hip joint but hip muscles declined with the disuse in ONFH patient. Our findings also suggest that not only underlying conditions but also postoperative muscle volume loss of the periprosthetic hip muscles due to disuse may be associated with unfavorable outcomes ONFH patients following THA.

SIGNIFICANCE/CLINICAL RELEVANCE: Periprosthetic hip muscles loss of postoperative ONFH patients on affected side may be associated with unfavorable outcomes following femoral osteotomy and primary THA.

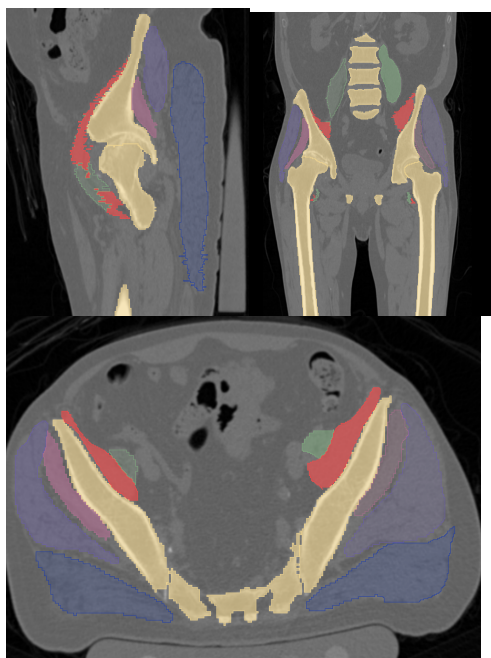


Figure.1

Open-source software 3Dslicer was utilized to identify iliopsoas, psoas major and minor, gluteus maximus, gluteus medius, gluteus minimus, ilium and sacrum in this CT views.

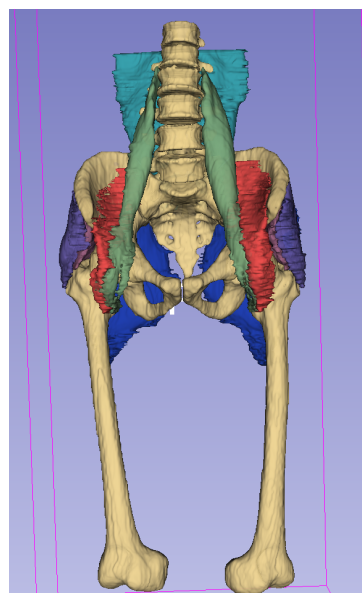


Figure.2

Three-dimensional images of trunk and hip muscles in 3D slicer.