

Longitudinal changes in medial joint space narrowing after medial meniscus posterior root repair

Koki Kawada, Takayuki Furumatsu, Masanori Tamura, Naohiro Higashihara, Yusuke Yokoyama, Toshifumi Ozaki
Department of Orthopaedic Surgery, Okayama University Graduate School of Medicine, Dentistry, and Pharmaceutical Science, Okayama, Japan
Email of Presenting Author: te4sf.stra.16@gmail.com

Disclosures: Koki Kawada (N), Takayuki Furumatsu (N), Masanori Tamura (N), Naohiro Higashihara (N), Yusuke Yokoyama (N), Toshifumi Ozaki (N)

INTRODUCTION: A medial meniscus (MM) posterior root tear (MMPRT) causes meniscal dysfunction and increases the contact pressure on the knee articular cartilage to a level equivalent to that of total meniscectomy. In recent years, MM posterior root repair has become the treatment of choice over conservative treatment or meniscectomy for improving symptoms and preventing knee osteoarthritis (OA) progression. Despite good clinical results, previous studies have reported that MM posterior root repair cannot completely prevent OA progression. This study aimed to evaluate longitudinal changes in medial joint space (MJS) narrowing during the first and second years after pull-out repair of MMPRT using fixed-flexion view (FFV) radiography (**Fig. 1**). We hypothesized that the progression of MJS narrowing would be slower in the second year than in the first year after repair.

METHODS: This retrospective study was approved by the Institutional Review Board of Okayama University (No. 1857). Written informed consent was obtained from all patients for the treatment and use of their data for research purposes. A total of 54 patients who underwent pullout repair for unilateral MMPRT were included in this study. FFV radiographs were obtained preoperatively and at 1- and 2-year post-repair to evaluate changes in the MJS. The change in the MJS width for each MM posterior root repair and contralateral knee was evaluated using the Wilcoxon single-rank test. Differences in MJS narrowing between MM posterior root repair and contralateral knees were evaluated using the Mann-Whitney U test.

RESULTS: The MJS widths for the MM posterior root repair and contralateral knees are shown in **Fig. 2**. The change in MJS for the MM posterior root repair knees was 0.48 ± 0.80 mm in the first year and 0.09 ± 0.36 mm in the second year after repair, with the change in MJS being significantly smaller during the second than the first year after repair ($p=0.002$). The change in MJS for the contralateral knees was 0.09 ± 0.49 mm in the first year and 0.07 ± 0.38 mm in the second year, with no difference between the two timepoints ($p=0.845$). The change in MJS was significantly greater in MM posterior root repair than in contralateral knees in the first year after repair ($p<0.001$); however, there was no between-side difference in the second year ($p=0.285$; **Table 1**).

DISCUSSION: FFV radiographs allow for a more accurate assessment of longitudinal changes in MJS narrowing. We used FFV radiographs to assess longitudinal changes in MJS narrowing after MM posterior root repair and compared them with those in contralateral knees. MM posterior root repair does not improve OA changes and, to some extent, further progresses OA. However, MJS narrowing in the second year after repair was comparable to that in contralateral knees. In the long term, narrowing of the MJS after posterior root repair of the MM may not be a concern.

SIGNIFICANCE/CLINICAL RELEVANCE: Changes in the OA after posterior root repair in MM are a major clinical issue. MJS narrowing of MM posterior root repair knees in the second year was comparable to that of contralateral knees.

IMAGES AND TABLES:

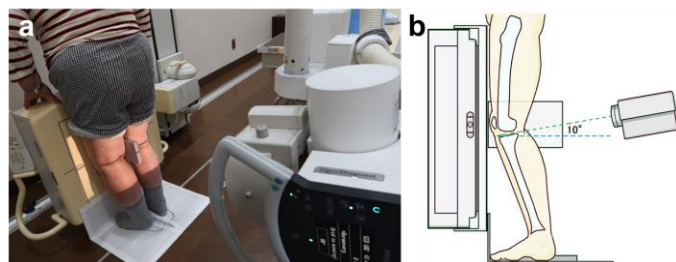


Fig. 1. FFV radiography methods.

(a) Patients stand on a custom-made limb positioning plate, with toes aligned to the plate. The device then externally rotated the foot to 5°.
(b) Schematic representation of the FFV methods.

Abbreviations: FFV, fixed-flexion view

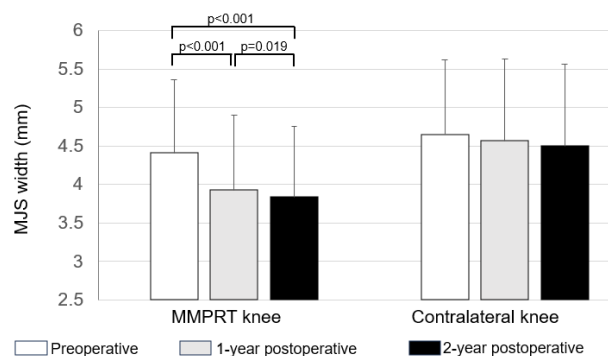


Fig. 2. MJS changes between the MMPRT and contralateral knees. MMPRT knees showed significant MJS narrowing preoperatively, as well as at 1 and 2 years postoperatively. In contrast, contralateral knees showed no significant narrowing of the MJS.
Abbreviations: MJS; medial joint space, MMPRT; medial meniscus posterior root tear

Table 1. Comparison of MJS width between the MMPRT and contralateral knees.

| | MMPRT | Contralateral | p-value |
|----------------------------------|-----------|---------------|---------|
| Preoperative MJS, mm | 4.41±0.84 | 4.65±0.96 | 0.166 |
| 1-year postoperative MJS, mm | 3.93±0.97 | 4.57±1.05 | 0.001* |
| 2-year postoperative MJS, mm | 3.84±0.92 | 4.50±1.05 | 0.002* |
| Change in MJS in the first year | 0.48±0.80 | 0.09±0.49 | <0.001* |
| Change in MJS in the second year | 0.09±0.36 | 0.07±0.38 | 0.285 |

Values are presented as the mean±standard deviation.

The between-side p-values were calculated using the Mann-Whitney U test.

*Statistically significant.

Abbreviations: MJS, medial joint space; MMPRT, medial meniscus posterior root tear