

Idiopathic carpal tunnel syndrome is not a single pathological condition: A study focusing on amyloid deposition in the carpal tunnel synovium

Yoshiaki Yamanaka¹, Takafumi Tajima¹, Yoshitaka Tsujimura¹, Toichiro Naito¹, Naohito Sato¹, Akinori Sakai¹

¹ Department of Orthopaedic Surgery, School of Medicine, University of Occupational and Environmental Health, Fukuoka, Japan

Disclosures: Yamanaka Y (N), Tajima T (N), Tsujimura Y (N), Naito T (N), Sato N (N), Sakai A (N)

Email : yamanaka@med.uoeh-u.ac.jp

INTRODUCTION:

The incidence of idiopathic carpal tunnel syndrome (CTS) peaks in middle-aged women at around 60 years of age, and in elderly individuals in general and men in particular after 70 years¹⁾. In contrast, transthyretin (TTR) amyloid is frequently deposited in the carpal tunnel synovium of elderly patients with CTS, and less frequently in middle-aged ones²⁾. This study aimed to clarify the differences in the pathogenesis of CTS among middle-aged women, elderly women, and elderly men who are at the peak of CTS incidence, with a focus on the presence of transthyretin amyloid deposition.

METHODS:

This study was approved by our Institutional Review Board, and informed consent was obtained from all patients who participated in the study. Intraoperative intracarpal tunnel synovium was obtained from patients who underwent surgery for idiopathic CTS, and the presence of TTR deposition in the synovium was evaluated by immunohistochemical staining. Fibroblasts were extracted from the remaining intracarpal synovium and divided into three groups: TTR-negative (TTR [-]) middle-aged women, TTR-positive (TTR [+]) elderly women, and TTR (+) elderly men, with 10 subjects in each group. The expression of fibrosis-related genes (Col1a1, Col1a2, Col3a1, transforming growth factor β 1 [TGF- β 1], and α SMA) in fibroblasts collected from the intracarpal tunnel synovium was compared among the three groups using quantitative real-time polymerase chain reaction. In addition, Boston carpal tunnel syndrome questionnaire (BCTQ) scores were compared preoperatively and 3 months postoperatively for clinical evaluation.

RESULTS:

Age was significantly higher in the TTR (+) elderly women (mean 78.3 years) and TTR (+) elderly men (mean 72.3 years) groups than in the TTR (-) middle-aged women group (mean 61.5 years) ($p < 0.01$). Col1a1, Col1a2, and TGF- β 1 were significantly upregulated in the TTR (+) elderly women compared to those in the TTR (-) middle-aged women and TTR (+) elderly men ($p < 0.05$, $p < 0.01$). α SMA was significantly upregulated in the TTR (+) elderly women group compared to that in the TTR (-) middle-aged women group ($p < 0.05$) (Figure 1). In the TTR (-) middle-aged women, the BCTQ-SS significantly improved at 3 months postoperatively (mean 18.9) compared to that preoperatively (mean 30.4) ($p < 0.05$) (Table 1).

DISCUSSION:

A remarkable characteristic of idiopathic CTS is the noninflammatory fibrosis of the subsynovial connective tissues in the carpal tunnel. Characteristic histological findings include hyperplasia of fibroblasts and blood vessels, thickened and disorganized collagen fibers, and an especially upregulated expression of not only collagen but also TGF- β 1 and its receptors³⁾. However, the involvement of TTR amyloid has recently been identified as one of the causes of idiopathic CTS. TTR amyloid deposition is seen in the heart and nerves, except in the carpal tunnel, and is termed ATTR amyloidosis²⁾. Based on the results of this study, the expression of Col1a1, Col1a2, and TGF- β 1 was upregulated in the TTR (+) elderly women, suggesting that fibrosis of the synovial membrane is one of the main pathological factors in carpal tunnel syndrome in elderly women. However, the lack of improvement in postoperative BCTQ scores with the surgical release of physical compression suggested that the median nerve itself may be accompanied by neuropathy due to TTR amyloid deposition. In contrast, the TTR (+) elderly men did not show any collagen hyperplasia or improvement in BCTQ scores, suggesting that the main pathophysiology is median neuropathy due to TTR amyloid deposition in the median nerve itself rather than physical compression due to fibrosis of the synovium. The TTR (-) middle-aged women did not show collagen hyperplasia but showed improvement in BCTQ scores, suggesting that physical compression other than fibrosis, such as edema of the synovium, may have been the cause; therefore, surgical decompression may have improved the BCTQ scores.

SIGNIFICANCE:

This study highlights that the pathogenesis of idiopathic CTS varies with age and the presence or absence of TTR amyloid deposition. These findings will be useful in predicting the treatment and prognosis for CTS in the future.

REFERENCES:

- 1) Incidence rates of in-hospital carpal tunnel syndrome in the general population and possible associations with marital status. BMC Public Health. 2008 Oct 28;8:374.
- 2) High prevalence of wild-type transthyretin deposition in patients with idiopathic carpal tunnel syndrome: a common cause of carpal tunnel syndrome in the elderly. Hum Pathol. 2011 Nov;42(11):1785-91.
- 3) A histological and immunohistochemical study of the subsynovial connective tissue in idiopathic carpal tunnel syndrome. J Bone Joint Surg Am. 2004 Jul;86(7):1458-66.

Figure1

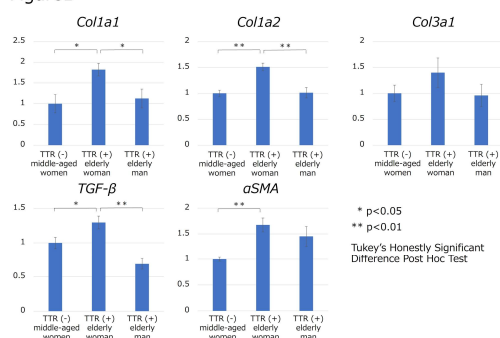


Table1

	Preoperation		Postoperation (3months)		p-value	
	BCTQ-SS	BCTQ-FS	BCTQ-SS	BCTQ-FS	BCTQ-SS	BCTQ-FS
TTR (-) middle-aged women group	30.4 \pm 7.9	20.6 \pm 6.4	18.9 \pm 4.8	14.3 \pm 3.1	0.001	0.08
TTR (+) elderly woman group	27.3 \pm 5.2	17.6 \pm 7.3	20.6 \pm 8.9	18.2 \pm 11	0.268	1
TTR (+) elderly man group	33.1 \pm 11.1	19 \pm 7.6	21 \pm 9.4	16.3 \pm 8.4	0.051	0.628

Average \pm Standard deviation